

Ultrasound diagnosis of cervical incompetence with cord prolapse

VO Ukwanya¹, AM Afodun² and KK Quadri³

*Department of Anatomy¹, School of Health and Health Technology,
Federal University of Technology, Akure, Department of Anatomy², College of Medicine,
University of Ilorin, Ilorin and Department of Physiology³, College of Medicine,
University of Lagos, Lagos, Nigeria*

Abstract

Cervical incompetence is a frequent cause of inevitable miscarriage in the second trimester, and it is often associated with a poor foetal outcome. Dilatation of the cervix was observed in a 31-year-old pregnant woman with previous preterm delivery. She presented with severe pelvic pains, preterm contractions and amniotic fluid discharge. Emergency abdominal sonography revealed polyhydramnios and umbilical cord prolapse. The cervical diameter measured 45 mm and the length measured 19 mm. The internal os was opened and showed conspicuous funnelling and protruding foetal leg through the internal os. The foetus was delivered by means of caesarean section and died about 24 hours later. This finding underscores the importance of ultrasonography to obstetricians and neonatologists and also highlights the need for routine obstetrics scan in patients at risk, especially in low income populations where such a procedure might be deemed as an unnecessary financial burden.

Keywords: *Cervical incompetence, dilatation, sonography, foetus, polyhydramnios*

Résumé

L'incompétence cervicale est une cause fréquente de fausse couche inévitable au deuxième trimestre, et elle est souvent associée à un mauvais résultat fœtal. Une dilatation du col de l'utérus a été observée chez une femme enceinte de 31 ans avec accouchement prématuré. Elle présentait des douleurs pelviennes sévères, des contractions prématurées et une décharge de liquide amniotique. L'échographie abdominale d'urgence a révélé un poly-hydramnios et un prolapsus du cordon ombilical. Le diamètre cervical mesurait 45 mm et la longueur mesurait 19 mm. L'orifice interne était ouvert et présentait un entonnoir visible et une jambe fœtale saillante à travers l'orifice interne. Le fœtus a été accouché par césarienne et est décédé environ 24

heures plus tard. Ces résultats soulignent l'importance de l'échographie pour les obstétriciens et les néonatalogistes et soulignent également la nécessité d'un examen obstétrical systématique chez les patients à risque, en particulier dans les populations à faible revenu où une telle procédure pourrait être considérée comme un fardeau financier inutile.

Mots-clés: *Incompétence cervicale, dilatation, échographie, fœtus, poly-hydramnios*

Introduction

Cervical insufficiency (CI) is a condition in which there is dilatation and shortening of the cervix before the 37th week of gestation in the absence of preterm labour [1]. It is characterised by a painless, progressive dilatation of the uterine cervix in the second or early third trimester, leading to membrane prolapse, premature rupture of the membranes, mid-trimester pregnancy loss or preterm birth [2].

CI is a rare medical condition. In Nigeria the reported incidence of CI is 0.78% [3]. Elsewhere, Lidgaard reported a CI incidence rate of 4.6 per 1000 births over a 10-year period using registry information of all hospitalised patients in Denmark [4]. In the USA the prevalence was estimated at 0.41% [5]. CI is also associated with genetic conditions. It has been reported in pregnancies involving women with the Ehlers–Danlos syndrome [6,7] and Marfan syndrome [8,9]. Polymorphisms in the COL1A1 and TGFBI genes have been associated with cervical insufficiency [10].

Cord prolapse is also a rare medical condition with a worldwide overall incidence of 0.2 – 0.6% [11]. Statistics from Nigeria also put the incidence rate for cord prolapse within 0.2 – 0.6% [11]. There is no diagnostic test for cervical insufficiency. However, recently, transvaginal ultrasonography has gained ascendancy as a demonstrable, valid and reproducible method of cervical assessment [12,13].

We present findings in a pregnant woman that came to our centre for routine obstetrics ultrasonography. She had a rare case of cervical incompetence combined with cord prolapse.

Case report

A 31-year-old pregnant woman G₂P₂⁰¹¹ in her second pregnancy was admitted to Crystal Specialist

Correspondence: Dr. Victor Ukwanya, Department of Anatomy, School of Health and Health Technology, Federal University of Technology, Akure, Nigeria. E-mail: voukwanya@futa.edu.ng; victorwyn@yahoo.com

Hospital, Lagos hospital at 31 weeks 4 days gestation. In her first pregnancy she had a preterm vaginal delivery at 27 weeks of gestation. She presented with severe pelvic pains, preterm contractions and amniotic fluid discharge. Emergency abdominal sonography revealed polyhydramnios and umbilical cord prolapse. The internal os was opened and showed conspicuous funnelling and protruding foetal leg into the introitus [Fig 1 A]. The cervical diameter measured 45 mm and the length measured 19 mm [Fig 1B].

shaped coupled with an opened internal os in ultrasound scan (as reported in this case) is a definitive indication of this clinical condition [15].

Available literature dwells extensively on the use of endovaginal cervical ultrasonography for the diagnosis of cervical incompetence [16,17,18]. However, in this study, the emergency of the patient's condition and the need to avoid further distress to the patient necessitated the use of trans-abdominal scan. Our findings proved that trans-abdominal sonography produced good results. This validates

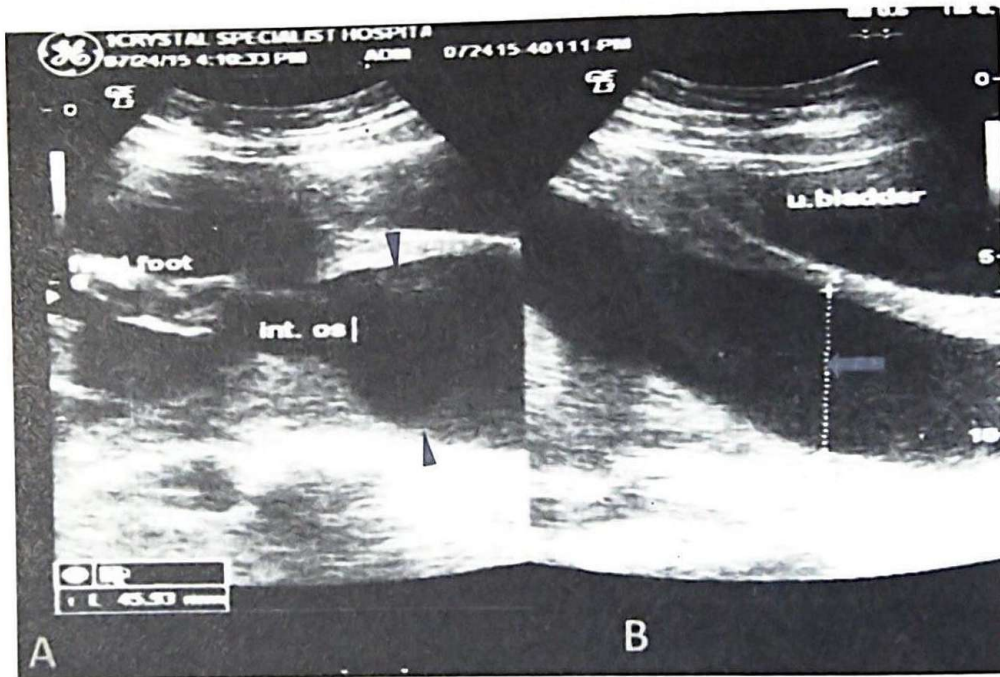


Fig. 1. Sonogram showing incompetent cervix. A. Observe the opened internal Os with the protruding foetal foot and the funnelling of the cervix (arrowheads). B. Observe the widened cervical diameter (block arrow).

A caesarean section was performed because of the cord prolapse and a baby boy was delivered with a birth weight of 1.93 kg. The neonate was admitted to the neonatal intensive care unit of the hospital where it was treated with antibiotics for congenital pneumonia. He died about 24 hours later.

Discussion

We reported a case of cervical insufficiency with occult cord prolapse. The cord prolapse necessitated emergency caesarean section to deliver the foetus.

Cervical incompetence is assessed by two main parameters, the cervical length and the appearance of the internal os. In this case we reported a cervical length of 19 mm and a funnel-shaped cervix using ultrasonography. The probability of preterm delivery is increased in cervical length less than 25 mm [14]. A dilated cervix appearing funnel-

the use of trans-abdominal scan as the initial sonographic technique for routine evaluation.

Caesarean section was necessitated by the cord prolapse which was occult in this case. Polyhydramnios and ruptured foetal membranes are known risk factors of cord prolapsed [20,21] and where present in this case. Cord prolapse is an obstetric emergency that should be delivered as soon as possible usually by caesarean section.

Cervical incompetence is often associated with poor foetal outcome and increased perinatal morbidity [22]. In this case the neonate died 24 hours after the preterm delivery.

This case further indicates the need for sonographic vigilance in gravid women with history of miscarriage so as to improve the prediction of the risk of actual preterm delivery. If the patient was under surveillance, the cervical insufficiency might have been discovered earlier to engender a better outcome.

Pregnant women with cervical incompetence usually present with subtle cervical dilatation between 16 and 24 weeks of gestation. Hence, serial obstetric scans within this critical window period would be highly recommended to diagnose the condition and avert preterm delivery.

Conclusion

This study underscores the importance of ultrasonography to obstetricians and neonatologists as an excellent diagnostic tool for the evaluation of the uterus and cervix in the gravid state. It also validates the need for routine obstetrics scan in patients at risk, especially in low income populations where such a procedure might be deemed as an unnecessary financial burden.

References

- McDonald IA. Incompetence of the cervix. *Aust N Z J Obstet Gynaecol.* 1978; 18:34-7.
- Shennan A and Jones B. The cervix and prematurity: aetiology, prediction and prevention. *Semin Foetal Neonatal Med.* 2004;9:471-479.
- Osemwenkha AP and Osaikhuomwan JA. Cervical cerclage in a Nigerian tertiary hospital: A review. *Niger J Surg Sci.* 24 (1): 1-6.
- Lidegaard O. Cervical incompetence and cerclage in Denmark 1980-1990. A register based epidemiological survey. *Acta Obstet Gynecol Scand.* 1994; 73:35-38.
- Schieve LA, Cohen B, Nannini A, *et al.* A population-based study of maternal and perinatal outcomes associated with assisted reproductive technology in Massachusetts. *Matern Child Health J.* 2007; 11:517-525.
- Leduc L and Wasserstrum N. Successful treatment with the Smith-Hodge pessary of cervical incompetence due to defective connective tissue in Ehlers-Danlos syndrome. *Am J Perinatol.* 1992; 9:25-27.
- De Vos M, Nuytink L, Verellen C and De Paepc. Preterm premature rupture of membranes in a patient with the hypermobility type of the Ehlers-Danlos syndrome. A case report. *FetalDiagn Ther.* 1999; 14:244-247.
- Meijboom LJ, Drenthen W, Pieper PG, *et al.* Obstetric complications in Marfan syndrome. *Int J Cardiol.* 2006; 110:53-59.
- Tzialidou I, Oehler K, Scharf A, Staboulidou I, Westhoff-Bleck M, Hillemanns P, Günter III (2007). Marfan syndrome in pregnancy: presentation of four cases and discussion. *Z Geburtshilfe Neonatol.* 211:36-41.
- Anum EA, Springel EH, Shriver MD and Strauss JF. III Genetic contributions to disparities in preterm birth. *Pediatr Res.* 2009; 65:1-9.
- Umaru UA, Gaya SA. Outcome of umbilical cord prolapse at Aminu Kano Teaching Hospital, Kano, North-Western Nigeria. *Niger J Surg Sci.* 2015; 12:20 - 24.
- To MS, Skentou C, Liao AW, Cacho A, Nicolaidis KH. Cervical length and funneling at 23 weeks of gestation in the prediction of spontaneous early preterm delivery. *Ultrasound Obstet Gynecol.* 2001; 18:200-203.
- Domin CM, Smith EJ and Terplan M. Transvaginal ultrasonographic measurement of cervical length as a predictor of preterm birth: a systematic review with meta-analysis. *Ultrasound Q.* 2010; 26:241-248.
- Iams JD, Goldenberg RL, Meis PJ, *et al.* The length of the cervix and the risk of spontaneous premature delivery. *N Eng J Med.* 1996; 334: 567 - 573.
- Miller ES, Gerber SE. Association between sonographic cervical appearance and preterm delivery after a history-indicated cerclage. *J Ultrasound Med.* 2014; 33 (12): 2181-2186.
- Guzman ER, Forster JK, Vintzileos AM, *et al.* Pregnancy outcomes in women treated with elective versus ultrasound-indicated cervical cerclage. *Ultrasound Obstet Gynecol.* 1998; 12(5):323-327.
- Leitch H, Bodner-Adler B, Brunbauer M, *et al.* Cervical length and dilatation of the internal cervical os detected by vaginal ultrasonography as markers for preterm delivery: A systematic review. *Am J Obstet Gynec.* 1999; 181(6):1465-1472.
- Chandra S, Crane JM, Hutchens D and Young DC. Transvaginal ultrasound and digital examination in predicting successful labor induction. *Obstet Gynecol.* 2001; 98(1):2-6.
- Chao A, Chao A, Hsieh PC. Ultrasound assessment of cervical length in pregnancy. *Taiwan J Obstet Gynecol.* 2008; 47(3): 291 - 295.
- Kahana B, Sheiner E, Levy A, Lazer S, Mazor M. Umbilical cord prolapse and perinatal outcomes. *Int J Gynaecol Obstet.* 2004; 84 (2): 127- 132.
- Hasegawa J, Ikeda T, Sekizawa A, Ishiwata I and Kinoshita K. Obstetrics risk factors for umbilical cord prolapse: a nationwide based study in Japan. *Arch Gynecol Obstet.* 2016; 291(1):5-7.
- Ayers JW, Peterson EP and Ansbacher R. Early therapy for the incompetent cervix in patients with habitual abortion. *Fertil Steril.* 1982; 38 (2) 177-181.