

## Hepatic changes induced by *Schrebera alata* (Hochst): a preliminary report on the toxicology of Il kau kawa

V. B-MBAYA

Department of Biochemistry, Faculty of Veterinary Medicine, University of Nairobi

### Summary

*Schrebera alata* is a deciduous fuel tree from which the Samburu people in Northern Kenya obtain bark for medicinal purposes. A pharmacologically active principle that produces analgesic effects can be extracted from the bark with hot water. When administered to rats daily for a period of 6 weeks, the extract of bark (referred to as Il kau kawa by the Samburu) caused reduced activities of succinic dehydrogenase, an enzyme that is involved in oxidative processes, and cholinesterase in heart and liver tissues. Histological sections from the liver revealed extensive cellular degeneration and small areas with necrotic lesions. Only that fraction of the bark extracts which contained components less soluble in alcohol produced such lesions within a 2 weeks period. The same fraction is associated with pharmacological activity.

Since hepatic injuries occur frequently and the incidence of primary hepatic carcinoma is high in tropical areas, the role of natural toxins as aetiologic factors for cirrhotic conditions must be adequately clarified. It is apparent that bark from *S. alata* possesses some toxicity and its effects on the liver indicate it can contribute significantly to prevalent hepatocellular damages.

### Résumé

*Schrebera alata* est un arbre duquel la tribu des Samburu de la Kenya du Nord obtient l'écorce pour l'usage médical.

La substance pharmacologique active qui exerce un effet analgésique, peut être extrait de l'écorce par de l'eau chaude.

Quand on administre aux rats journellement l'extrait de l'écorce appelé par des Samburu (Il

Correspondence: Dr Vertestine Mbaya, Department of Biochemistry, Faculty of Veterinary Medicine, Chiromo University of Nairobi, Nairobi, Kenya.

kau kawa), pour une période de six semaines, les activités de l'hydrogenase succinique, enzyme qui joue un rôle important dans des processus oxydatifs et de l'esterase de choline dans les tissus du coeur et du foie sont réduites.

Des préparations histologiques du foie démontrent une dégénération cellulaire extensive et des zones limitées des ulcérations nécrotiques. Ce n'est que la partie de l'écorce qui contient des substances insolubles dans l'alcool, qui produit les ulcérations dans une période de deux semaines. La même partie est associée avec l'activité pharmacologique la plus prononcée.

Le nombre des lésions hépatiques étant nombreux dans les régions tropicales, le rôle des toxines naturelles, jouant une importance ethnologique dans les dégénération cirrhotiques doit être éclairci d'une façon satisfaisante. Il est apparent que l'écorce de Samburu *alata* possède de toxicité et son effet sur les tissus hépatiques indique qu'elle peut contribuer aux dégâts hepatocellulaires d'une façon significative.

Il kau kawa is a medicinal preparation from the bark of the deciduous tree, *Schrebera alata*. It is used by the Samburu people of Northern Kenya for the alleviation of pain or other discomforts resulting from respiratory infections. The medicinal substance is obtained from the dried bark by steeping it in hot water and the resulting solution is frequently consumed as a tea or mixed with milk. Other species, *Schrebera galuncensis* and *Olea africana* Mill., have been employed by the Masai, the Wemba of Southern Africa and the Thlaping as headache remedies and eye lotions (Williamson, 1955; Watt & Breyer-Brandwijk, 1962).

After verbal reports on the effectiveness of Il kau kawa as an analgesic drug, investigations of its pharmacological and toxic properties were initiated.

A report on the pharmacological activity in various extracts from the bark has been prepared by Dr Lowell Parsons.<sup>1</sup> The study reported here describes apparent toxic effects of the aqueous extracts of the bark and the early hepatocellular changes.

#### Materials and methods

Dried bark from *S. alata* in Nairobi was ground to a fine powder. An aqueous extract of the bark was obtained by mixing the powder with hot water and allowing the particles to settle for 20 min. Centrifugation of the mixture produced a clear supernatant that was added to a basic diet of 15 g of the commercial 'Vitamealo' preparation containing 20% protein, cereal products and essential vitamins for each animal.

White male rats from a stock bred in this institution were housed individually and assigned to two experimental groups at the age of 3 months. In experiment 1, fifteen rats received the aqueous extract from 2.5 g of bark in their feed daily for 6 weeks. Twelve rats received only the 'Vitamealo' diet.

In experiment 2, three groups of four rats received one of three different extracts daily for 2 weeks. Ethanol and ether extraction techniques (Sunshine, 1969) produced preparations containing the acid and neutral drugs, the basic drugs, or the alcohol insoluble components from 1g of the powdered bark.

The rats were killed by cervical fracture except for four rats which received CO<sub>2</sub>. Samples from each organ were fixed in buffered formaline for paraffin sections or placed in buffered glutaraldehyde.

<sup>1</sup> Correspondence: Dr Lowell Parsons, Ahmadu Bello University, Zaria, Nigeria.

post-fixed in osmium tetroxide and embedded in Araldite. The remainder of each organ was homogenized in cold phosphate buffer and the activities of cholinesterase (de la Hueraga, Yesinick & Popper, 1952), succinic dehydrogenase Thurberg & Ahlgren method (Oser, 1965) and cytochrome oxidase were determined in the homogenates (Smith & Stotz, 1949).

#### Results

Except for an initial loss in weight which was subsequently regained, the general appearance and appetites of the test rats remained similar to that of the controls. However, the activities of certain enzymes and histological examinations indicated the early stages of cardiac and hepatic damage. Rats which had received the aqueous extract daily for 6 weeks showed a reduction of succinic dehydrogenase and cholinesterase activities (Tables 1 and 2). Frequently, the livers of these rats revealed 50% less dehydrogenase activity than those from control animals. Cholinesterase activities were generally 30% lower in the liver, but in the heart were similar to the control values. The values for cytochrome oxidase by the method employed revealed little difference between control and experimental rats.

Histologically, varying degrees of cellular deterioration were revealed in the livers of rats fed *S. alata*. Acidophilic changes in the periportal areas as well as hemosiderin deposits were seen in paraffin sections. The hepatocytes contained pyknotic nuclei and translucent cytoplasmic inclusions (Fig. 1a) reminiscent of the hyaline bodies described

TABLE 1. Succinic acid dehydrogenase activities in rat liver and heart

	No. of rats	Min required for reduction of methylene blue by 100 mg tissue (mean $\pm$ s.e.)	Range
Controls			
Liver	12	20.8 $\pm$ 0.9	16-26
Heart	12	17.0 $\pm$ 0.9	14-22
Test rats			
Each rat received 2.5 grams of <i>Il kau kawa</i> daily for 6 weeks.			
Liver	15	30.0 $\pm$ 1.4	22-40
Heart	15	29.5 $\pm$ 1.4	24-40



TABLE 2. Cholinesterase activities in rat liver and heart

	No. of rats	Enzyme activity (mean)	Range
Controls			
Liver	12	8.5	6.5-10.0
Heart	12	9.0	7-10.0
Test rats			
Each rat received 2.5 g of <i>Il kau kawa</i> daily for 6 weeks.			
Liver	15	5.5	5.4-5.7
Heart	15	7.5	6.7-10.0

by MacDonald (1961). The glycogen content, as revealed by staining with periodic acid and the Schiff's reagent, was markedly reduced, but liposis hardly occurred when compared to the extensive fatty changes caused by ethionine or choline deficiency. Thinner sections (0.5-1  $\mu$ m) showed more clearly the areas of cellular damage. Patches of necrotic cells occurred in the periportal regions as well as more extensive necrotic lesions that involved portal and central zones of the liver lobule (Fig. 2). Particularly noticeable in these liver sections was the accumulation of cytoplasmic material that stains metachromatically with toluidine blue in contrast to the blue colour of other cellular components

(Fig. 1b). Although hepatocytes in normal liver sections contain small quantities of the chromotropic material also, it appears uniformly distributed between areas of the ergastoplasm. However, the chromotropic content of parenchymal cells in damaged tissue increased substantially and frequently occupied most of the available cytoplasm from which other cellular components were largely excluded.

When subjected to the electron microscope, these spaces of chromotropic material appeared congested with mitochondria and smaller vesicles in close proximity to isolated cisternae of the granular reticulum (Fig. 3). The more random distribution

TABLE 3. Cholinesterase and succinic acid dehydrogenase activities in rats fed extracts of *Schrebera alata* for 2 weeks

	No.	Succinic dehydrogenase (minutes required for reduction of methylene blue by 100 mg of tissue) (Mean $\pm$ s.e.)	Cholinesterase (Mean activity)
Controls			
Liver	5	13.0 $\pm$ 0.5	8.5 $\pm$ 0.5
Heart	5	14.0 $\pm$ 1.0	9.0 $\pm$ 0.5
Rats fed acid and neutral components			
Liver	4	15.0 $\pm$ 0.6	6.0 $\pm$ 0.4
Heart	4	20.0 $\pm$ 1.0	7.0 $\pm$ 0.5
Rats fed water-insoluble components			
Liver	4	18.0 $\pm$ 1.0	8.0 $\pm$ 0.5
Heart	4	19.5 $\pm$ 0.9	8.5 $\pm$ 0.6
Rats fed alcohol insoluble components			
Liver	4	15 $\pm$ 0.5	10.0 $\pm$ 0.5
Heart	4	25 $\pm$ 0.5	14.5 $\pm$ 1.0

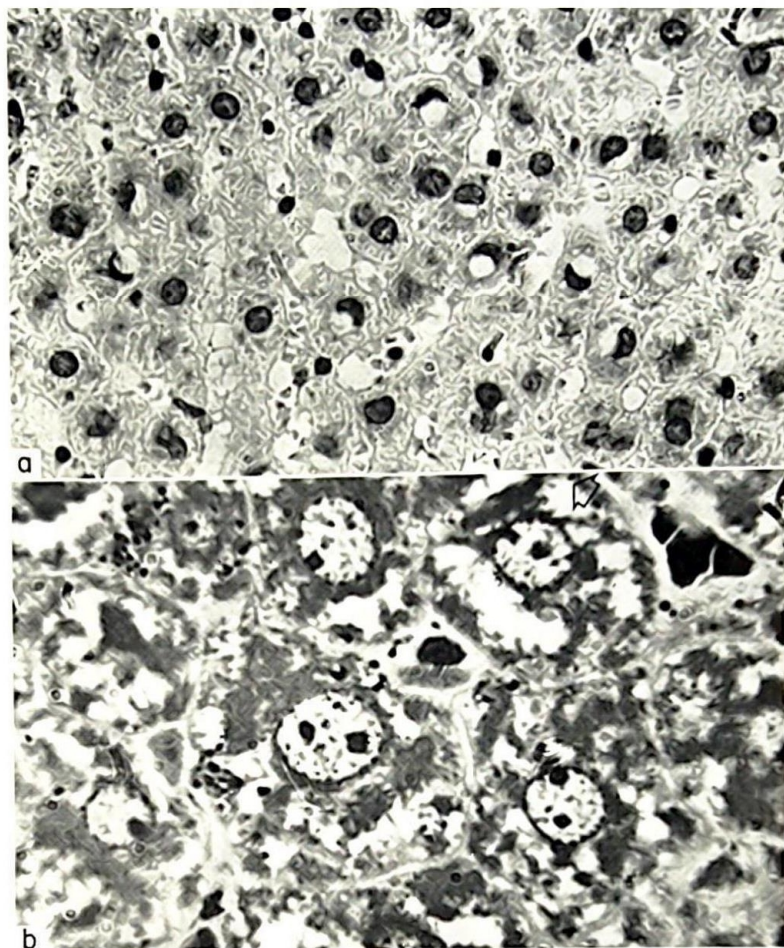


FIG. 1. (a) Formalin fixed paraffin section from liver of rat fed aqueous extract of *Schreberia alata*. Cells of the periportal region with pyknotic and translucent inclusions bordering nuclei are seen. Stained with haematoxylin and eosin.  $\times 480$ . (b) Parenchymal liver cells of rat fed the bark extract with cytoplasmic inclusions that stain metachromatically with toluidine blue (the whitish areas). The inclusions appear to be aggregations of globules circumscribed by translucent borders that exhibit metachromasia more intensely (arrow). The chromotropic material is not apparent in the nucleus. Embedded in araldite.  $\times 1250$ .

of these organelles throughout the cytoplasm was replaced by aggregations of mitochondria with central areas of ergastoplasm, and the greater portion of remaining cytoplasm was occupied by several large clusters of particulate glycogen. The masses of glycogen which are normally dispersed throughout the cell among smaller aggregates of the carbohydrate were crowded together into a few areas so that a small number of collections, but hardly any single aggregates of glycogen, were

observed. Diminution of both granular and agranular reticulum was apparent. The agranular reticulum was hardly noticeable since those areas not occupied by assemblies of mitochondria contained, for the most part, the enlarged masses of glycogen aggregates. The tubular structure of the granular reticulum was less evident than expected and many groups of free ribosomes were seen near mitochondria.

Results from the second trial with extracts



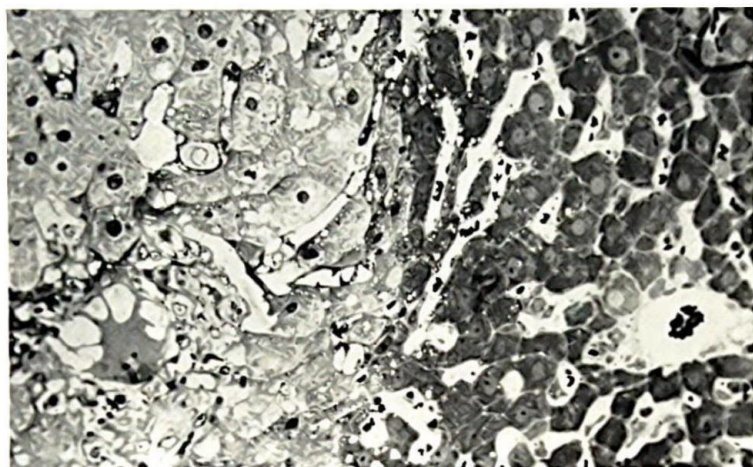


FIG. 2. To the right is seen pronounced hepatocellular degeneration involving the centrolobular region in a rat fed the bark extract. The presence of some nearly normal cells may be indicative of regenerative activity in that area. Embedded in araldite. Stained with toluidine blue.  $\times 300$ .

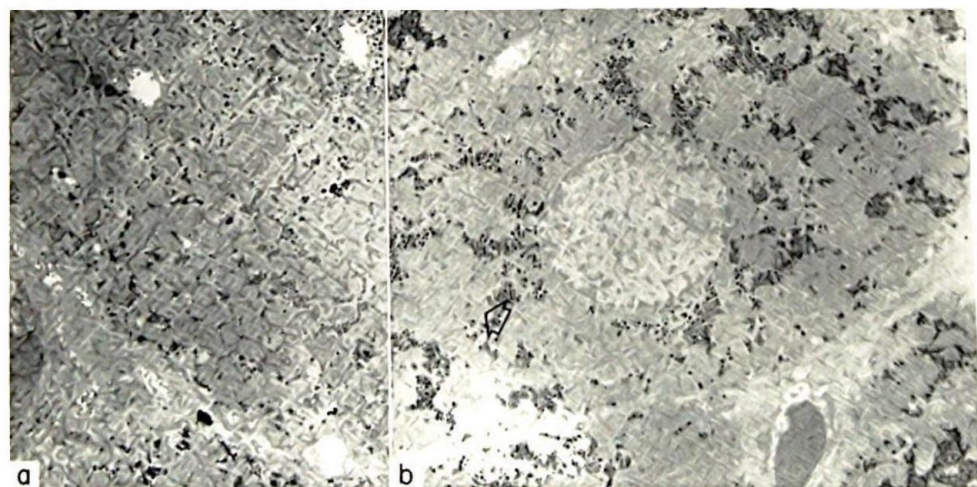


FIG. 3. (a) Mitochondria as seen in normal rat livers. Note the more even distribution of the organelles. Buffered glutaraldehyde and osmium fixation. Lead citrate staining. (b) Hepatic cells from II kau kawa fed rats with the mitochondria assembled around granular reticulum (arrow). Such collections are most obvious in cells showing excessive clumps of metachromasy.  $\times 4800$ .

containing the acid and neutral drugs, basic constituents or the alcohol insoluble substances suggest that the hepatic changes observed may be due to components less soluble in alcohol. Within 2 weeks those histological changes in the liver described above occurred in rats receiving the latter extract. Pre-

liminary trials indicate that this fraction also exhibits pharmacological activity.

#### Discussion

The metamorphosis of liver tissue into cirrhotic or



necrotic lesions can be induced by a variety of factors such as infections, malnutrition and toxins. Malnutrition and toxins have become particularly important considerations in the aetiology of liver diseases in tropical areas, although the relative significance of these factors as causative agents of hepatic injuries is largely unknown. Toxins from food or herbal sources, such as that from the cycad nut, may be contributing factors to the high incidence of hepatocellular failure in some areas.

Very little appears in the literature about the use of *S. alata* as a curative. Its use among the Samburu was reported by a graduate student who also utilized the drug for a toothache while completing his investigations. The tree is hard and heavy and has been used mainly as firewood by various groups in Kenya (Dale, 1936), but several related species are utilized as medicinals more extensively. *Olea africana* Mill. has been employed as an eye wash lotion in man and in animals by the Thlaping as well as a headache remedy by the Wasotho in South Africa (Watt & Breyer-Brandwijk, 1962). Masai drink an infusion of *Olea chrysohylla* Lam. as a remedy for rheumatism (Williamson, 1955). Several species of the Olive family (in which *S. alata* is classified) contain violent toxins. The berries from one of these, *Liqustrum vulgare* (privet) contain the toxic principle syringin, a D-glucoside (Smith, 1923).

Although the manifestations of hepatic damage is of limited variety, the pathogenesis of the lesions produced by hepatotoxins may be influenced by the agent responsible. Ethionine produces fatty livers without necrosis whereas thioacetamide produces hepatocellular necrosis and hardly fatty change (Ashworth *et al.*, 1965). The hepatocellular injury induced by *S. alata* resembles more the pattern of hepatic damage due to thioacetamide. There was insignificant fat accumulation, but a marked dispersal as well as reduction of the ergastoplasmic components. The loss of succinic dehydrogenase activity from the liver cells is also a common effect. Toxins as carbon tetrachloride or tannic acid as well as dietary deficiencies may cause similar injuries but these substances or conditions cause fatty metamorphosis also (Rouiller, 1964). Eventually most toxins effect alterations in the size and number of mitochondria although mitochondrial lesions may occur earlier with one type of intoxication than with another. Swollen mitochondria have been described in the early stages of intoxication with

carbon tetrachloride, phosphorus, ethionine, and thioacetamide (Rouiller, 1964). Besides swelling, mitochondrial changes may involve the disruption of the membranes and the disappearance or granulation of the cristae. The organelles may increase in number also, particularly during the period of regeneration that follows acute intoxications. Alteration of mitochondrial size and number was hardly discernible during the study with *S. alata*, however, the loss of granules and cristae was evident. More obvious were the clumps of mitochondria and smaller vesicles that encircled isolated areas of ergastoplasmic fragments and occupied only several parts of the cytoplasm. A similar distribution of mitochondria occurs in liver cells injured by butter yellow whereas normal parenchymal cells are generally filled with mitochondria in all parts of the cytoplasmic region (Opie, 1947). Additionally, an accumulation of double membraned vesicles resembling degenerate mitochondria has been observed in the hepatic tissue of rats subjected to vitamin E deficiency (Hartroft, 1964).

The ingredients in *S. alata* that provoke hepatocellular lesions or serve as an analgesic are still unknown. However, it is evident that a section of the population in Kenya is consuming a herbal preparation that is likely to contain toxic principles.

#### Acknowledgments

The author acknowledges with gratitude the efficient participation of the technical staff in this laboratory and the assistance of Dr Lowell Parsons who supplied the first samples of *Schrebera alata*. I also thank Dr Wangari Mathai, a collaborator in other studies, who assisted in the processing of histological sections with other members of her staff.

#### References

- ASHWORTH, C.T., WERNER, D.J., GLASS, M.D. & ARNOLD, N.J. (1965) Spectrum of fine structural changes in hepatocellular injury due to thioacetamide. *Am. J. Path.* **47**, 917-951.
- DALE, I.R. (1936) *Trees and shrubs of the Kenya colony*, p. 127. Government Printer, Nairobi.
- DE LA HUEGA, I., YESINICK, C. & POPPER, H. (1952) A colorimetric assay for cholinesterase and acetylcholinesterase. *Am. J. Clin. Path.* **22**, 1126-1133.
- HARTROFT, W.S. (1964) Electron microscopy of liver and kidney cells in dietary deficiencies, in cellular injury (Ciba Foundation Symposium), pp. 248-279. (Ed. by de Reuck, A.V.S. & Knight, J.). J & A Churchill, London.



- MACDONALD, R. (1961) Experimental carcinoma of the liver. *Am. J. Path.* 39, 209-220.
- OPIE, E. (1947) Normal structure and degenerative changes of cytoplasm of liver cells and of tumor cells derived from them. *J. exp. Med.* 85, 339-346.
- OSER, B. (1965) *Hawk's Physiological Chemistry*, 14th edn. McGraw-Hill, Inc., New York.
- ROUILLER, CH. (1964) *Experimental toxic injury of the liver, in the liver*. Vol. II, pp. 335-476. Ed. Rouiller, C., Academic Press, N.Y. & London.
- SMITH, A.B. (1923) *Poisonous plants of all countries*, 2nd edn, p. 70. Bailliere, Tindall & Cox, London.
- SMITH, F.G. & STOTZ, E.S. (1949) A colorimetric method for the determination of cytochrome oxidase. *J. biol. Chem.* 179, 891-901.
- SUNSHINE, I. (1969) *Handbook of Analytical Toxicology*. pp. 394-396. Chemical Rubber Co., Ohio.
- WATT, J.M. & BREYER-BRANDWIJH, K.M. (1962) *Medicinal and poisonous plants of South and Eastern Africa*, 2nd edn., pp. 805-809. E.S. Livingstone Ltd., London.
- WILLIAMSON, J. (1955) *Useful plants of Nyasaland*, p. 86. Government Printer, Nyasaland.

(Received 18 June 1973)