

**AFRICAN JOURNAL OF
MEDICINE**
and medical sciences

VOLUME 32, NO 1

MARCH 2003



EDITOR
B. O. OSOTIMEHIN

ASSISTANT EDITOR
A. O. UWAIFO

ISSN 1116—4077

Recurrent leg ulcers in a 16-year old Nigerian girl

AO Afolabi

Department of Surgery, University College Hospital, P. M. B. 5116, Ibadan, Nigeria.

Summary

This is a report of a 16-year old Nigerian girl who presented with recurrent leg ulcers associated with gastrointestinal symptoms. The management of this patient, who has ulcerative colitis manifesting with pyoderma gangrenosum, underlines the need for thorough evaluation of cutaneous ulcers in the tropics. The medical treatment of ulcerative colitis in childhood, with reservation of bowel resection for complications is preferred.

Keywords: *Leg ulcers, ulcerative colitis, pyoderma gangrenosum, childhood*

Résumé

C'est un rapport sur une fille Nigérienne âgée de 16 ans et admise à l'hôpital ayant des abcès permanents à la jambe associée aux symptômes gastro-intestinaux. Le ménagement du malade qui a une ulcération colique se manifestant avec des pyodermes gangreneuses relève le besoin d'une évaluation des ulcères cutanés dans les tropiques. Le traitement médical de l'ulcération colique dans l'enfance avec reservation de resection de l'estomac pour les complications est préféré.

Case report

A 16-year old girl presented with a history of recurrent multiple leg ulcers of one-year duration. She had recurrent painful swelling of both ankles and the right knee previously. She was pale and had bilateral multiple leg ulcers measuring 1 - 3 cm in diameter, with sloping edges, necrotic floor, soft tender bases free of the tibia, and dark peripheral skin. There was a 16 cm by 6 cm hypopigmented scar on the anterior surface of the right leg. However the ankle and knee joints were normal. She had anal skin tags at 5, 7 and 11 o'clock. A clinical diagnosis of rheumatoid arthritis with recurrent leg ulcers was made. The wound culture yielded a heavy growth of *Staphylococcus aureus*. The chest radiograph was normal, and right leg radiograph

showed a soft tissue defect. The haemoglobin level was 3.8 g/dl and the erythrocytes showed a picture of mixed anaemia. The leukocyte count was 10,000/mm³ and the E.S.R. was 150 mm/hr (Westergreen). The haemoglobin genotype was A. The serum globulin was high at 4.1 g/dl. The stool microscopy, urinalysis, and other serum chemical parameters were normal. The Coomb's tests, latex test for rheumatoid factor, and H.I.V. screening were negative. She later developed bloody mucoid diarrhoea preceded by colicky abdominal pains. She then gave a history of recurrent bloody diarrhoea of five-year duration. The bone marrow smear showed a reactive picture. The fine needle aspirate biopsy of the ulcer edges suggested benign infective ulcers. The diagnosis of an inflammatory bowel disease manifesting with pyoderma gangrenosum was considered. A colonoscope could not be passed beyond 12 cm from the anal verge. Therefore, rigid proctoscopy and rectal biopsy were performed. Barium enema showed narrowing of the rectum and anastomosis of the colon. The histology of the rectal tissue showed features suggestive of ulcerative colitis. She was commenced on intravenous methylprednisolone sodium succinate 40 mg stat, oral prednisolone 20mg b.d. and oral olsalazine 500 mg b.d. These were complemented with retention enema of methylprednisolone. She improved clinically and was discharged home on treatment with olsalazine, prednisolone, mist magnesium trisilicate, folic acid, fersolate, vitamin C, and wound dressing. The leg ulcers healed after nine weeks. However, the tapering of the dosage of Prednisolone was followed by recurrence of bloody diarrhoea and pyoderma gangrenosum. The dose of Prednisolone was restored to 20 mg b.d. Over the next six weeks the bloody diarrhoea stopped and the ulcers healed. She was maintained on methylprednisolone, olsalazine and gelusil, and was being followed up. She defaulted on follow-up from the clinic where the diagnosis was made, for about six months, because her symptoms resolved. However, she re-presented to me at my current institution when rectal bleeding recurred, with a packed cell volume of 16%. The rectal biopsy was repeated and the histology, performed by another pathologist, was suggestive of ulcerative colitis (Figure 1). The barium enema was repeated and it showed free flow of barium from the rectum to the caecum and anastomosis of the descending and

sigmoid colon (Figure 2). She was recommenced on prednisolone, sulfasalazine, gelusil, and haematinics. The symptoms resolved and she was followed up.

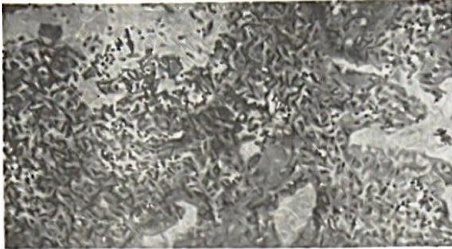


Fig. 1: Photomicrograph of rectal biopsy tissue showing focal mucosal ulceration and non-specific chronic inflammation with infiltration of lamina propria with plasma cells, macrophages and lymphocytes (arrow) (Haematoxylin and Eosin, $\times 16$).



Fig. 2: Photograph of barium enema film showing ahaustation of rectosigmoid and descending colon.

Discussion

Pyoderma gangrenosum is an uncommon cutaneous disorder that often begins as a small pustule. It results in localised skin destruction characterised by an expanding ulceration with undermined violaceous borders [1]. It is often associated with underlying systemic diseases, the most common of which is an inflammatory bowel disease [2]. Pyoderma gangrenosum is rare in childhood. In a series, only 4% of the patients were younger than 15 years [3]. Ulcerative colitis (26%) was the common underlying aetiology in the 74% who had a systemic illness. It was followed by leukaemia, Crohn's disease, and HIV infection [3]. Inflammatory bowel disease was considered in this patient because of the association of pyoderma gangrenosum with abdominal pains, bloody diarrhoea,

anaemia, arthralgia, leucocytosis, and hyperglobulinaemia. The initial ulcers healed over a 5-month period of regular dressing elsewhere, without a specific treatment for pyoderma gangrenosum. The associated features raised our index of suspicion for an inflammatory bowel disease, which is considered uncommon in Nigeria. Although the rectal stricture and abdominal pains suggest Crohn's disease, the medical management of ulcerative colitis and the former is similar [4]. The differential diagnosis is imperative for surgical management. The successful control of the entero-colonic inflammation with methylprednisolone and olsalazine, and the healing of the cutaneous ulcers made us to temporise on the surgical treatment of the bowel disease. However, the steroid-dependence of the patient may indicate early colonic surgery to prevent the side effect of prolonged steroid therapy. This is because bowel resection may be rewarded with a prompt or very slow healing of the pyoderma gangrenosum [3]. The morbidity of bowel resection and a stoma necessitated a prolonged medical management of this patient. Cyclosporin, a useful treatment for refractory lesions, may be considered if the cutaneous ulcers fail to heal after bowel resection. Pyoderma gangrenosum, though uncommon in childhood, should be well investigated to enable proper management of the underlying systemic disorder. Cutaneous leg ulcers are common in childhood in the tropics. The healing of such ulcers on regular dressing may prevent a thorough investigation for specific causes. This case report underlines the need for a thorough evaluation of refractory cutaneous ulcers in the tropics. A high index of suspicion for the rare systemic causes of ulcers is advocated.

Acknowledgements

I acknowledge the management and staff of Crest Consultant Clinic, S. W. Ikoyi, Lagos, Nigeria, where the patient was managed initially; Dr C. C. Chibututu, with whom the colonoscopy was attempted; Dr O. Banjo and Dr. J.O. Ogunbiyi, the pathologists who performed the histology of the rectal biopsy specimens independently.

References

1. Dourmishev A L, Miteva I, Schwartz R A. Pyoderma gangrenosum in childhood. *Cutis* 1996; 58(4): 257 - 62.
2. Tay Y K, Fiednash M, Aelin J L. Acute pyoderma does not require surgical therapy. *Archives of Family Medicine* 1998; 7(4): 377-80.
3. Lionetti P, Batinni M L, Resti M, Falcini F. A 14 - year old girl with skin ulcers. *Lancet* 1998; 351: 262.
4. Joseph B K. Historical origins of medical and surgical therapy of inflammatory bowel disease. *Lancet* 1998; 352: 1303 - 05.