

**AFRICAN JOURNAL OF  
MEDICINE  
and medical sciences**

**VOLUME 31, NUMBER 1 MARCH 2002**



**EDITOR:  
B. O. OSOTIMEHIN**

**ASSISTANT EDITOR:  
A. O. UWAIFO**

**ISSN 1116 — 4077**



## Evaluation of the effectiveness of post-operative beta-irradiation in the management of pterygium

BGK Ajayi and CO Bekibebe

Ojulowo eye Hospital, Alawiye House Mokola, Ibadan and Department of Ophthalmology, University College Hospital, Ibadan, Nigeria.

### Summary:

A retrospective review of cases of pterygium excision using the bare sclera method followed by application of 2500-3500 rads of Sr 90 beta-radiation carried out between 1994 and the year 2000 at Ojulowo Eye clinic Ibadan and St Mary's Catholic Specialist Eye Hospital Ago-Iwoye, Nigeria. Follow up period was between six months and six years. A total of 124 eyes from 95 patients were operated. 58(61.1%) were males and 37(38.9%) were females. The youngest patient was 10 years old while the oldest was 89 years mean 46.1 ± 2 STD of 13.5. Most pterygia were unilateral and nasal in location. Improvement in visual acuity of between 2-6 lines on snellen chart occurred in 6(4.8%) of operated eyes. Recurrence necessitating repeat surgery and additional radiation occurred in 8 eyes (6.9%). The complications of surgery and beta radiation consisted of conjunctiva inflammation 10(8.6%), cornea opacities 4(3.2%), gritty sensation 3(2.6), cataract 1(0.8%). No case of sclera necrosis was observed. Post-operative beta-radiation is safe and effective in preventing recurrence of pterygium.

**Keywords:** pterygium, beta-irradiation, pterygium excision.

### Résumé

Pour passer en revue le resultat de l'excision a l'irradiation - beta du pterygium une revue retrospective des cas d'excision du pterygium par la methode de la sclera suivi de l'application beta effectuée entre 1994 et l'an 2000 a Ojulowo Eye clinic, Ibadan et St Mary's Catholic specialist Eye Hospital, Ago - Iwoye, Nigeria. La periode de suivi etait entre 6 mois et six ans. Un total de 124 yeux de 95 malades ont ete operes. 58 (61, 1%) etaient des homes et 37 (38, 8%) de femmes. Le plus jeune patient avait 10 ans alors que le plus age avait 89 ans, moyenne 46, 1±2, STD=13,5. La plupart des pterygies etaient des homes et 37 (38,8%) de femmes. Le plus jeune patient avait 10 ans alors que le plus age avait 89 ans, moyenne 46, 1±2, STD=13,5. La plupart des pterygies etaient unilaterales et localisees dans le nez. L'amélioration de l'acuite visuelle entre 2-6 lignes de la carte snellen ont eu lieu dans 6(4, 8%) des yeux operes. La recurrence, necessitant une seconde intervention chirurgicale et une dose seconde de radiation ont apparus dans 8 yeux (6,9%). Les complications chirurgicales et des radiations beta ont consistes de l'inflammation de la conjonctive 10(8, 6%) l'opacite de la cornee 4(3, 2%), sensation serree 3(2, 6%), cataracte 1 (0, 8%). Aucun cas de necrose sclerale etait observe. L'apres operation de radiation - beta est sans resurgance du pterygium.

### Introduction

Pterygium is a degenerative eye disease presenting clinically as a triangular shaped growth of fibro-vascular tissue in the palpebral aperture with extension into the cornea. The etiology

of pterygium is not precisely known but has been associated with exposure to ultra-violet light [1], chronic ocular irritation by dust and other environmental factors [2,3].

Treatment for pterygium is surgical excision of the growth for a number of reasons including cosmetic, persistent eye irritation, itching, redness of the eye and visual impairment [4]. Simple excision of pterygium is associated with recurrence in 40-96% of cases [4,5]. The use of additional treatment modalities such as conjunctiva graft, anti-metabolites or Beta radiation is therefore necessary. Rethy et al in 1972 reported a success rate of 100% following post-operative beta-radiation of vascularised pterygium in Lagos. An earlier attempt by the authors to use about the same dose of beta radiation resulted in a sizable number of recurrence. Thus the need to find a safe level of beta radiation for our patients with fleshy and often advanced pterygium. No reported work has been done in Ibadan since 1991 when Ashaye reported a recurrence rate of pterygium excision with bare sclera technique of 40% and advocated the use of beta-radiation. Facilities for beta-radiation became available in Ojulowo Eye Hospital in Ibadan in 1991. Patients from other eye clinics are therefore referred there for beta-radiation. This study is therefore a review of the outcome of post operative beta-radiation treatment for pterygium with focus on recurrence rate and complications as indices of quality of care.

### Materials and methods

Retrospective review of case notes of all patients who had pterygium excision with beta-radiation from January 1994 to February 2000 was carried out at the Ojulowo Eye clinic, Ibadan and St Mary's Catholic Eye Hospital, Ago-Iwoye. The minimum follow up period was six months while the maximum was 8 yrs. 53 patients were followed up for between 6 months and one year, and 32 for between 1 year and 6 years. 8 patients who defaulted between one and three weeks were excluded from the final analysis. 75 patients who had pterygium surgery by the same method and varying amount of beta-radiation during the initial trial period between 1991 and 1993 December (following dosages recommended by previous authors [5]) were excluded because a standard procedure was not used.

Information obtained include, age, sex, occupation, number of eyes treated. Location of pterygium (vascularized or atrophied), surgical procedure with date, amount of beta radiation given with date, presence and extent of pterygium recurrence post-operatively with date, intra-operative and post-operative complication, duration of post operative observation. All cases had pterygium excision by the bare sclera method [6].

### Radiation technique

The source of the beta radiation for all the patients was the strontium 90/yttrium 90 pterygium applicator SIA 20. The applicator contains an insoluble strontium 90 compound



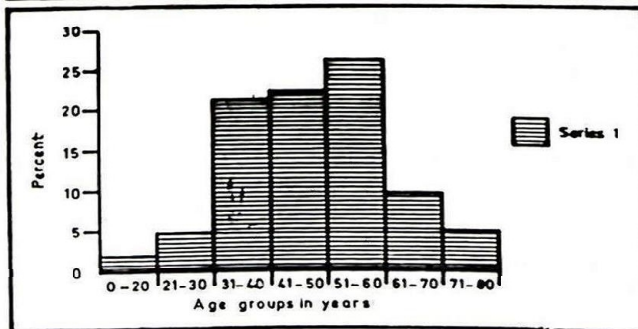
incorporated in a rolled silver disc with a face thickness of 0.05mm. The disc is sealed in a stainless steel holder having a window thickness of 0.05mm. The steel holder is attached to a handle having swivel joint which allows the active head to be rotated through 180 degrees and which is fitted a perspex shield to protect the operator. The Sr 90 half life is 28.6 years. The radiation emitted by the source consist of 0.546 mev. of beta rays through which strontium decays to yttrium and the 2.274 mev. beta rays through which yttrium decays to stable zirconium. The surface dose is 50 rads/sec. The dose to eye tissues decreases with depth of tissue. At surface level 100% dose is received, between 3-6mm depths (level of the crystalline lens) less than 20% of surface dose is received. The active area may be reduced by fitting a metal shield with a kidney shaped aperture over the active face. However in the treated group, the shield on the active face was completely removed and the entire surface of the applicator (whose active diameter is 8.5mm) was applied to the bare area of the pterygium bed. This was as a result of our initial experience when recurrences were often observed above and below the area of exposure. Thus the entire area of the pterygium bed which is much larger than the manufacturers recommendation was covered with a mild overlap of the adjacent limbal cornea. All applications were done within twenty-four hours of surgery.

After anaesthetizing the eye, the applicator was placed in direct contact with the point of the surgical severance of the head of the pterygium and left for the time required to give the prescribed dose (50-70 seconds) ranging from 2500-3500 rads administered typically in one fraction. In some cases (18/124), additional 2500 rads was given after one week depending on the size and vascularity of the pterygium. In calculating the dose correction was made for decay in the activity of the Sr 90 source which decreases with time as shown on the manufactures scale provided. The patients were subsequently commenced on prophylactic antibiotic ointment, and steroid eye drops to reduce inflammation. Follow up was initially at one week followed by three-week intervals.

### Results:

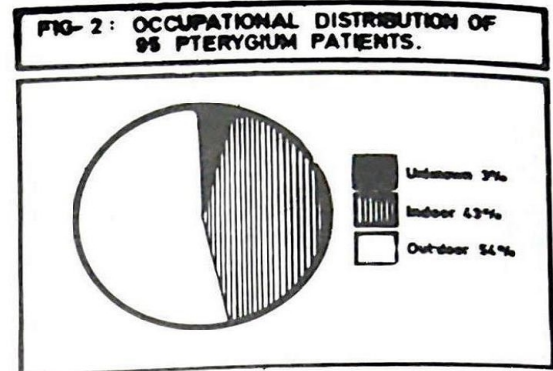
A total of 124 pterygium excisions with beta-radiation from 95 patients were reviewed. There were 58 (61.1%) males and 37 (38.9%) females (ratio 1.6:1). The youngest age was 10 years and the oldest 89 years. The mean age was 46.1 years  $\pm$  2 standard deviation of 13.5 (Fig 1).

FIG. 1: AGE DISTRIBUTION OF 95 PTERYGIUM PATIENTS



The occupational distribution was varied and included traders, farmers, students, civil servants, priests, field workers, masons, bankers and teachers.

When grouped into indoor and outdoor activities, those who were predominantly indoor workers were 41 (43.2%) and outdoor workers 51 (53.7%). Fig. 2



Location of pterygium: 29 patients had bilateral pterygia while 66 had it in only one eye. Table 1 shows the details of the location of pterygium. All the patients treated had vascularized pterygia, 15 eyes had recurrent pterygia following simple excision done elsewhere.

Table 1: Site of Pterygium in 95 patient

Location	No	%
Temporal	04	3.2
Nasal	112	90.3
Combined nasal and temporal	08	6.5

Visual acuity: 6 (4.8%) of operated eyes had improvement in visual acuity of 2-6. Lines on the snellen chart, while 2 (1.6%) had a reduction.

### Recurrence of pterygium following beta-radiation:

18 eyes (14.5%) showed initial presence of recidives following pterygium excision with beta-radiation but only 8 eyes (6.9%) progressed to have corneal extension requiring repeat surgery and additional beta radiation. The remaining 10 cases had regression or non-progression of the residives. 5 of these patients with recurrence did not consent to repeat surgery. 2 of the recurrences occurred from an inferior portion of the initial pterygium that escaped the beta-radiation field. They were successfully treated with repeat surgery and beta-radiation. The 8<sup>th</sup> patient was free from further recurrence only after four repeat surgeries with beta-radiation. The total cumulative of beta radiation given was about 7000 rads. The earliest recurrence observed was at one week while the latest was at 5 months, with a mean of about 2 1/2 months.

Complications: No intra-operative complications were observed. The post-operative complications however consisted of prolonged inflammation in 10 cases (8.6%) and gritty sensation in 3 cases (2.6%), cornea opacity 4 (3.2%), cataract 1 (0.8%). No case of sclera necroses was seen.

### Discussion

Pterygium is a fairly common eye condition in tropical countries and although not a common cause of blindness may be a source



of annoyance for the patient through its cosmetic effect, impairment of vision and ocular irritation<sup>4</sup>. It occurred in all age groups in this series but was predominantly in the 5<sup>th</sup> and 6<sup>th</sup> decades. This finding is in keeping with previous reports.<sup>4,6</sup> The sex distribution is similar to previous reports<sup>1</sup> and is expected since males are usually more involved with outdoor activity. Majority of the pterygia were present in one eye and were in most cases nasally located. These are also in keeping with previous observations.<sup>4</sup> The predominant nasal location among other factors has been ascribed to effect of reflection of ultraviolet radiation by the bridge of the nose on to the nasal conjunctiva [7]. Recurrence of pterygia following beta-radiation necessitating re-operation was seen in only 6.9% of the patients reviewed. This is a great improvement compared to recurrence rate of 40% by simple excision without beta-radiation reported by Ashaye in 1991. This therefore justifies the earlier call for beta-radiation for the post-operative treatment of pterygia by Ashaye.

The recurrence rate of 6.9% in this series is however higher than Rethy's figure of 0% recurrence but similar to Bernstein's and Unger's values of 3/46 (6.5%)[8] and lies within Cooper and Irving's reported 0-24% recurrence rates [9]. Rethy did not state exactly what percentage of their 148 progressive pterygia actually had beta-radiation thereby making more objective comparisons of statistical values impossible. Factors, which have been said to affect recurrence of pterygia following beta-radiation, include, the dose, interval between surgery and radiation with optimal doses of 3000 rads for the average pterygium or recurrence given within 4 days of surgery [2]. Age and sex have been said to have no effect on recurrence [9]. There was improvement in vision in 4.8% of eyes following surgery. This is not surprising since many patients in the study environment present late when vision is already compromised by the advancing pterygium head overlying the visual axis. The complication rates in this study were within acceptable limits

and comparable to those of previous reports[8].

#### Conclusion

Pterygium excision has been reported to have very high recurrence rate necessitating several repeat surgeries. This review has shown that beta-radiation post-terygium excision is both safe and effective in reducing the usually high recurrence rate of pterygium. It is therefore recommended that beta-radiation be administered to more cases of vascularized fleshy pterygium to prevent recurrence.

#### References

1. Cameron, ME : pterygium throughout the world Springfield, Illinois: Charles C. Thomas publisher. 1965.
2. Detels, R and Dhir, SP : pterygium: A geographical study. Arch ophthalmol. 1967, 78: 485-491.
3. Hill JC and Maske, R. : Pathogenesis of pterygium. Eye, 1989; 3: 218-226.
4. Ashaye AO : Pterygium in Ibadan. W.A.J.M. 1991, vol 10, 3 and 4, 232-243.
5. Rethy I, Fregene A.O, Salomon K. Post-operative beta-radiation of pterygium in Nigeria; Nigerian Medical Journal, 1973; 3: (4) 196-197.
6. D'Ombrian, A: The surgical treatment of pterygium. Brit. J. Ophthalmol. 1948; 32-65.
7. Isyaku, M. Pterygium pathogenesis: another hypothesis: Nigerian Journal of Ophthalmology, 1996; 4: (1) 31-32.
8. Bernstein, M. Unger, S.M: Experiences with surgery and strontium-90 in the treatment of pterygium. Am.J. Ophthalmol. 49: 1024-1029.
9. Cooper J.S, Irving A.L. Post-operative irradiation of pterygium an unexpected effect of the time/dose relationship. Radiology, 1980, 135: 743-745.