Afr. J. Med. med. Sci. (1990) **19**, 145–151.

Carotid angiography in a teaching hospital in Saudi Arabia

T. M. KOLAWOLE, P. J. PATEL, A. M. AL-MUZRAKCHI AND TAJUDDIN MALABAREY
College of Medicine (40), King Saud University, Riyadh, Saudi Arabia

Summary

The carotid angiographic studies performed in a teaching hospital (King Khalid University Hospital, Riyadh) in Saudi Arabia were reviewed, and the incidence of lesions demonstrated was analysed. Intracranial tumours accounted for 50% of the lesions, with meningiomas being 40%, whilst arteriovenous malformations accounted for 5.9% of lesions. It was noted that the incidence of atherosclerosis and arteritis was low, and the examination was almost without complications. Some lesions supplied by vertebral arteries were missed. In view of this, vertebral angiography is advocated in those cases with suspected supratentorial tumour especially when the carotid angiograms are normal.

Résumé

Nous avons revisé les angiographies carotidiennes qui ont été faites à l'hôpital de CHU de Riyade. Notre étude démontre que 50% des lésions ont été des tumeurs intracraniennes, parmi elles 40% meningiomes; et 5.9% des lésions ont été des malformations artério-véneuses. L'incidence de l'artériosclérose et l'artérite était bas. Les complications des angiographies ont été très rares. Parfois les lésions qui sont fournis par les artères vertébrales sont manqués. Pour cela l'angiographie carotidienne est recommandé où il y avait des soupçons de tumeurs supratentoriennes, particulièrement lorsque l'angiographie carotidienne est normale.

Correspondence: Dr T. M. Kolawole, PO Box 10219, Riyadh 11433, Saudi Arabia.

Introduction

A review of cranial angiography in King Khalid University Hospital in Riyadh, Saudi Arabia over a 33-month period beginning from May 1983 was undertaken with a view to finding out the diagnostic efficiency in an era of computerized tomography (CT) as well as establishing the distribution of lesions and their angiographic characteristics.

Materials and methods

A total of 67 carotid angiograms were carried out during the period of study. However, only 40 films were available for study.

Results

The age of these 40 patients ranged between 1 and 76 years with an age peak during the fourth decade of life. The sex ratio was 3M:2F.

Table 1 shows the various types of examinations. Vertebral studies were carried out in 25% of patients and formed the only study in 5% of cases. Left and right carotid injections were carried out in 60 and 70% of patients, respectively, whilst bilateral carotid studies were the only studies in 35% of patients. The frequency of symptom complexes is shown in Table 2 with hemiparesis, epilepsy and visual disturbances each occurring in about 25% of the patients.

Table 3 shows the types of lesions seen and proven by surgery and with most confirmed pre-operatively by CT. Meningiomas and arteriovenous malformations occurred in 55% of cases. Ten cases were diagnosed as normal. Six of these revealed lesions on CT, as shown in Table 4.

Table 1. Types of examinations

Type of angiograms	Number of patients studied	Percentage
Bilateral carotids and vertebral	5	12.5
Bilateral carotids only	9	22.5
Total bilateral carotids	14	35
Left carotid and vertebral	3	7.5
Left carotid only	7	17.5
Right carotid and vertebral	0	0
Total left carotids	10	60
Right carotid only	14	35.5
Total right carotids	28	70
Vertebral only	2	5.0
Total vertebral only	10	25
Total	40	100

Table 2. Main presenting symptoms

Main features	Number of cases
Hemiparesis	10
Epilepsy	9
Visual disturbances including proptosis	7
Headaches	4
Ataxia	2
Coma	1
Dysphasia	1
Vomiting	1
Tremors	1
Neck swelling	1
Head numbness	1
Dizziness	1

Table 3. Types of lesions occurring

Type of lesions	Number of cases
Normal	5
Meningiomas	16
Arteriovenous malformations*	7
Glioma	4
Pituitary masses	3
Intracerebral haemorrhage/ infarction	4
Subdural haematoma	1
Carotid body tumour	1
Total	41

*Occurred with a glioma.

Intracranial tumours accounted for 50% of the lesions, among which was a total of 16 meningiomas with a sex ratio of 7M:9F and with 50% of them occurring in the 40–60 years of age group and a male–female sex ratio of 1:3. The five patients presenting with visual symptoms were all of the sphenoidal bone origin, and there were four with hemiparesis; all of which are on the left and parasagittal in origin.

The distribution of the meningiomas is as follows:

(1) sphenoidal — 7 cases (3M:4F);
(2) fronto-parietal — 7 cases; and
(3) cerebropontine angle — 3 cases, one with a fronto-parietal meningioma.

Discussion

In most centres, the frequency of angiograms diminishes with the utilization of CT scanners unless interventional neuroradiology is practised. However, the frequency of cranial angiography has stabilized at about 30 per year since early 1985, despite the installation and utilization of a Siemens Somatom 2 CT scanner. The absence of a decline in the frequency of angiograms may be explained by the increase in total hospital patient number, as well as the use

Table 4. Analysis of 10 cases with normal angiographic diagnosis

Type of diagnosis	Number of cases
No CT/surgical confirmation	3
Infarction	2
Normal CT	1
Cerebellopontine angle tumour	1
Frontal lobe glioma	1
Arteriovenous malformation*	1
Sphenoidal meningioma	1
Empty sella	1
Total	11

*Occurred with a glioma.

of angiograms to tide over down-times on the CT scanner.

The higher male ratio in our cases is in keeping with other studies, and that of hospital admissions in King Khalid University Hospital in general [1].

Seventy per cent of cases with angiograms had CT scan confirmation. However, it is a common practice here that many lesions seen on CT scans require no further angiographic studies before the commencement of specific treatment.

The diagnostic accuracy of the 40 angiographic studies was quite high (85%). When it is recognized that cases of empty sella and cerebral infarction (without intracerebral haemorrhage/oedema) are normal, the diagnostic accuracy would rise to 92.5%.

Only two complications documented angiographically were seen; one with embolus in the facial artery and another with haematoma around the site of puncture. Again, the paucity of complications is an index of the high expertise available in King Khalid University Hospital.

Arteriovenous malformations and meningiomas were the commonest lesions seen.

Vascular malformations

One of the arteriovenous malformations was an aneurysm of the vein of Galen in a two-year-old male who presented with exophthalmos and had a bruit rather than cardiac failure which is the commonest presenting sign [2]. Angiography revealed aneurysm with its dilated and multiple feeder vessels, as well as its rapid flow and drainage into the straight sinus and torcula (Fig. 1a). CT not only confirmed this but, as expected, revealed the associated ischaemic changes (Fig. 1b). No hydrocephalus was seen.

Fig. 1. (a) Aneurysmal dilatation of the vein of Galen with a dilated straight sinus fed by numerous arteries arising from the middle cerebral artery. (b) Enhanced CT of the brain showing aneurysm of the great vein of Galen draining into a distended straight sinus and torcula. Note the atrophy of the brain, especially frontally.

A carotid body tumour is a vascular tumour which has some of the angiographic characteristics of an arteriovenous malformation with dilated arteries and fast flow into multiple and dilated veins, and can be confused with arteriovenous malformations [3]. However, the site of lesion, the neovascularity and the marked splaying of the carotid bifurcation which typifies it differentiate it from arteriovenous malformations (Fig. 2a–c).

Complications

There was only one case of a small atherosclerotic lesion seen at the carotid bifurcation. The low incidence of aneurysms, arteritis, and carotid artery atherosclerosis in this series is significant.

Meningiomas

The angiographic appearances of the meningioma seen were as expected and previously described in the literature [4,5]. Displacement of vessels, especially of contralateral shift of the anterior and middle cerebral arteries depends on the site and size of the tumour. Basal

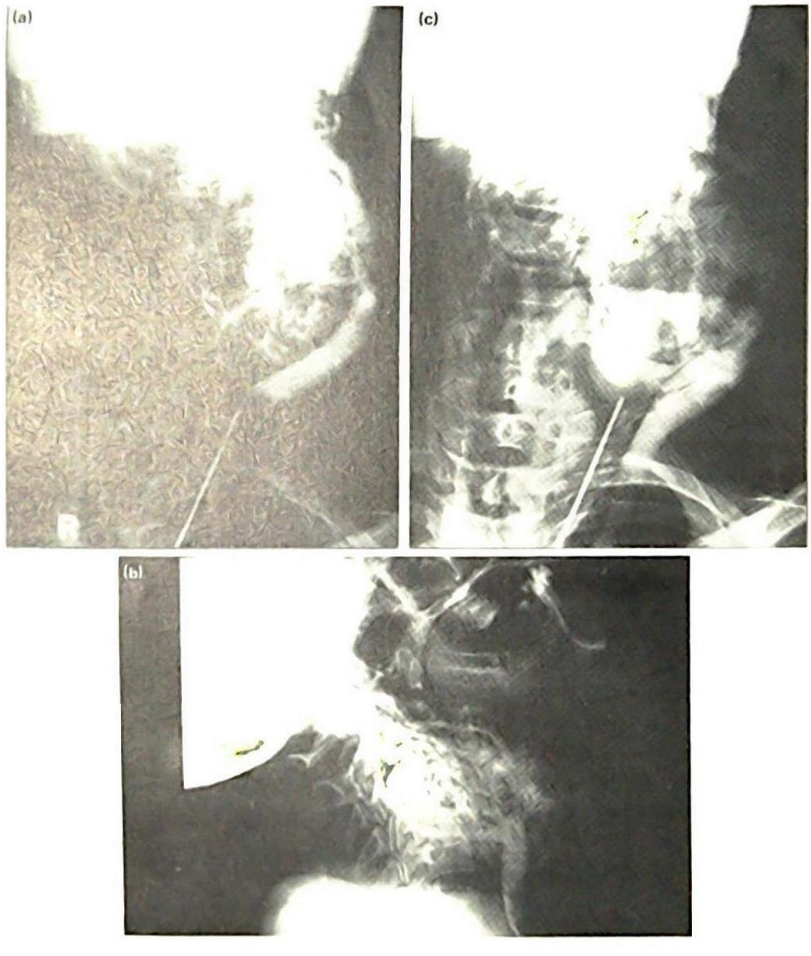

Fig. 2. (a) Antero-posterior view of a carotid body tumour. Common carotid injection opacity: a very vascular tumour displacing the carotid arteries laterally. (b) Lateral view demonstrating splaying of the internal and external carotid arteries by a vascular tumour. Venous phase showing delayed opacification of the tumour with markedly dilated draining veins, especially the jugular veins.

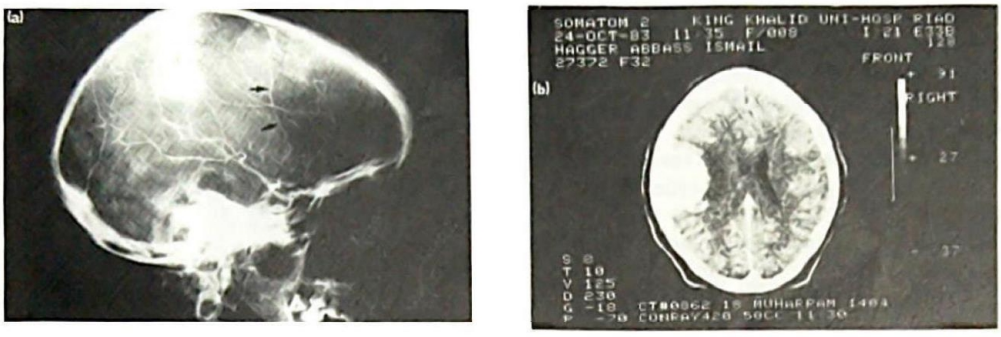

Fig. 3. (a) Lateral view of carotid angiogram showing anterior parietal blush fed by arteries, one (external carotid branch) of which shows paradoxic enlargement (↑). (b) CT of brain from (a). Homogenous area of high attenuation values contiguous to internal table in the left parietal region and with some compression of the left lateral ventricle.

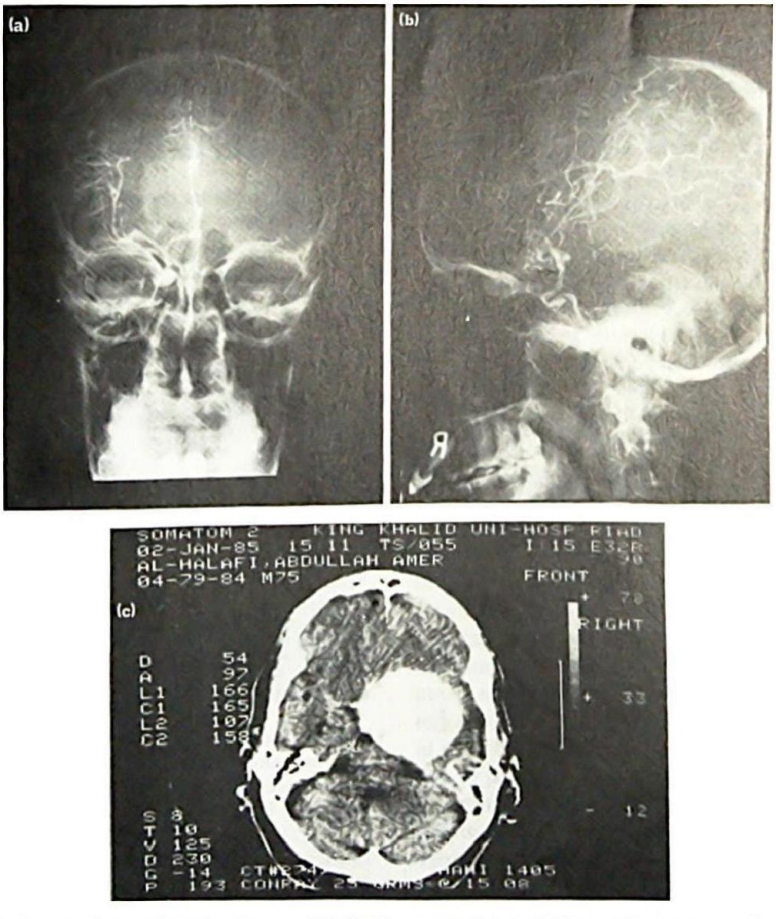

Fig. 4. (a) Antero-posterior view showing medial displacement of the middle cerebral artery and with minimal shift of the anterior cerebral artery by a sphenoid wing meningioma extending posteriorly. The proximal segment of the anterior cerebral artery is slightly elevated. (b) Lateral view of same patient showing subfrontal extension. Posterior displacement of the post-clinoid carotid artery and the proximal portion of the anterior carotid artery (↑) and with elevation of middle cerebral artery. (c) CT scan of same patient. Large homogenous tumour in the right middle fossa extending subfrontally and medially compressing the suprasellar cistern.

meningiomas showed no significant shift. Essentially, in all cases, there was vascularization of the mass adjoining the inner table with early draining veins or obliteration of adjacent veins by pressure.

Tumour stain was seen in all cases; and in two cases the meningeal supply to the tumour was clearly demonstrated.

The typical paradoxical enlargement of the arteries and the classical sunburnt angiographic appearance depicting the hilus of the tumour were also seen [4] (Fig. 3a and b).

In the single case of falcine meningioma, characteristic splaying of the anterior cerebral arteries was seen; but the typical vascular supply from the anterior meningeal branch of the ophthalmic artery [5] (or anterior ethmoidal branches) or the supply by a sub-occipital branch of the vertebral artery arising from below the foramen magnum was not seen [6].

Sphenoidal wing meningiomas presented as part of their symptoms, complexes with visual disturbances caused by pressure effects on the optic nerves. They are peculiar in having varied angiographic appearances depending on the direction of growth of the tumour. They may grow medially and frontally and present as subfrontal masses [4]. Posterior displacement of the anterior cerebral artery is the main and possibly the only change seen angiographically (Fig. 4a–c). Most present as infrasylvian tumours, elevating and displacing the middle cerebral arteries upwards and medially. Midline shift of the anterior cerebral arteries is usually nil or minimal due to the 'obstructing wall effect' of the sphenoidal bone in the midline (Figs 4a and 5). Sometimes the tumour extends medially towards the sella displacing the supraclinoid portion of the internal carotid artery medially.

One case of sphenoidal wing meningioma and two of cerebellopontine meningioma, one coexisting with a convexity meningioma, were missed because a vertebral angiogram was not taken. A vertebral angiogram is mandatory in suspected sphenoidal wing meningioma, or any supratentorial tumour including the cerebellopontine angle tumours, if the carotid angiographic studies are normal. The posterior cerebral arteries (branches of the vertebral artery) sometimes feed sphenoidal wing meningiomas through the arterior temporal arterial branches (Fig. 6), or may supply the posterior parietal meningiomas by the parietal branches of the posterior cerebral arteries. Tentorial meningiomas, which present as cerebellopontine tumours, could be identified by the characteristic elevation of the posterior cerebral artery and the depression of the superior cerebellar artery [7,8] (Fig. 7). How-

Fig. 5. Antero-posterior view of an angiogram of a sphenoidal wing meningioma. Note elevation and medial displacement of the post-clinoid carotid and middle cerebral artery. The cavernous carotid is stretched with its distal aspect displaced medially. Note the minimal shift of the anterior cerebral arteries.

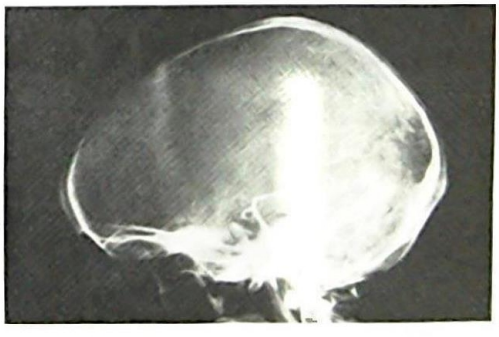

Fig. 6. Lateral vertebral angiogram showing an anterior temporal branch of the posterior cerebral artery feeding a sphenoidal wing meningioma depicted by hyperostosis.

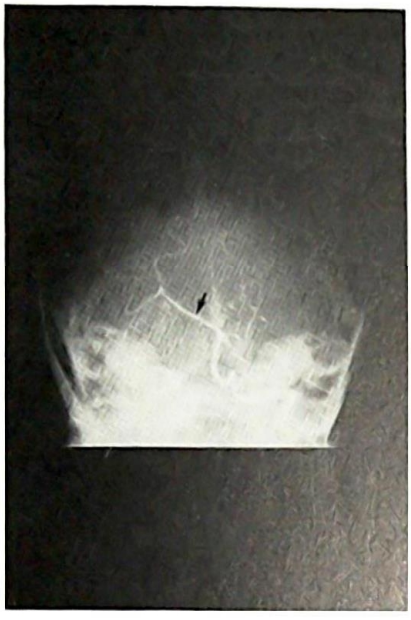

Fig. 7. Vertebral angiogram with elevation of the right posterior cerebral artery (↑).

ever, they are usually fed by the posterior branch of the middle meningeal artery or the meningohypophyseal branch of the internal carotid artery [4]. Cerebellopontine tumours are usually supplied by the anterior–inferior cerebellar arteries.

Computerized tomography should be the first radio-diagnostic examination in suspected intracranial lesions. However, angiography is mandatory in vascular lesions and should be used to elucidate the vascular supplies of tumours as a pre-operative procedure.

References

1. Patel PJ, Kolawole TM, Mandhi AH, Oteishat WA. Computed tomography (CT) scan and findings in children with seizures only. Acta Neurologica 1986;74:165–6.
2. Martelli A, Scotti G, Harwood-Nash DC, Chuang SH. Aneurysm of the vein of Galen in children — CT and angiographic correlations. Neuroradiology 1980;20:123–33.
3. Bateson EM, Bull T. Two unusual tumours of the chemoreceptor system with angiographic demonstration. Br J Radiol 1967;40:120–4.
4. Nasher HC, Crote W, Lohr E, Gerhard L. Multiple meningiomas: clinical and computed tomographic observations. Neuroradiology 1981;21:259–63.
5. Taveras JM, Wood EH. Carotid angiography diagnosis of intracranial masses by vascular displacement. In: Diagnostic Neuroradiology, Vol. II. Baltimore: Williams & Wilkins Co. 1976:670–747.
6. Banna M, Appleby A. Some angiographic observations in supratentorial meningiomas. Clin Radiol 1969;20:375–86.
7. Hawkins TD, Melcher DH. A meningeal artery in the falx cerebri. Clin Radiol 1966;17:377–83.
8. George AE. A systematic approach to the interpretation of posterior fossa angiography. Radiol Clin N Am 1974;22:271–300.

(*Accepted* 14 *September* 1987)