

# AFRICAN JOURNAL OF MEDICINE and medical sciences

VOLUME 34 NUMBER 2

JUNE 2005



*Editor-in-Chief*  
**YETUNDE A. AKEN'OVA**

*Assistants Editor-in-Chief*  
**A. O. OGUNNIYI**  
**O. D. OLALEYE**

ISSN 1116-4077



## Pulmonary alveolar microlithiasis – a case report

\*GO Omoniyi-Esan, \*\*IA Adediran, \*\*\*OC Famurewa and \*KB Badmos

*\*Departments of Morbid Anatomy and Forensic Medicine, \*\*Haematology and Immunology and \*\*\*Radiology, Obafemi Awolowo University, Ile Ife, Nigeria*

### Summary

Pulmonary alveolar microlithiasis (PAM) is a rare disease of unknown aetiology. It is characterized by the presence of calcific concretions (calcospherites) inside the alveoli [1]. We present a case of a 22year old sickle cell anaemia patient with an incidental finding of PAM. This report is to highlight the fact that though rare, PAM is not entirely unheard of in this environment and should be kept in mind as a cause of diffuse opacities of the lungs.

**Keywords:** *Pulmonary, alveolar microlithiasis.*

### Résumé

La microlithiasie alvéolaire pulmonaire (MAP) est une maladie rare d'étiologie inconnue. Elle est caractérisée par la présence d'accumulation de calcifique dans les alvéoles. Nous présentons le cas d'un patient drépanocytaire anémié de 22 ans avec une incidence de la MAP. Ce rapport illumine le fait que, bien que rare la MAP est entièrement inattendu dans cet environnement et doit être reconnu comme une cause des opacités diffuse des poumons.

### Introduction

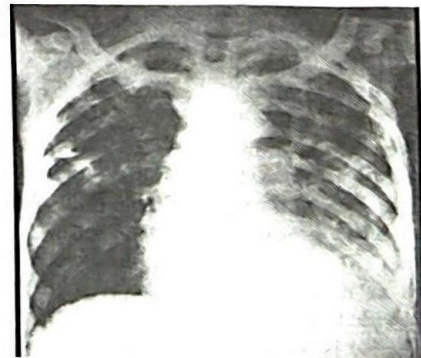
Pulmonary alveolar microlithiasis (PAM) is a rare disease of unknown aetiology. It is characterized by the presence of calcific concretions (calcospherites) inside the alveoli [1]. The disease was first described in 1918 by Harbitz [2] but it was not until 1933 that Pühr [3] gave the disease, the name, alveolar microlithiasis. Generally, patients present with few clinical symptoms like cough and chest signs which are not usually specific. Chest X-ray appearances include bilateral diffuse pulmonary infiltration of miliary pattern and the pathognomonic sand-like opacifications which are usually seen throughout the lungs [4]. High resolution CT (HRCT) findings of diffuse ground glass opacities, interlobular septal thickenings and linear calcification along the pleura have been described [5,6]. Bronchoalveolar lavage and transbronchial biopsy show the characteristic calcospherites in the recovered lavage fluid in the alveolar spaces [6,7].

It is noteworthy that only about 200 individual and small group case reports have been documented since the disease was discovered [6,7,8,9,10]. Onadeko *et al* reported the first case of PAM in Sub-Saharan Africa in 1977 based on radiological examination and lung biopsy [12]. We report a case of PAM in a Sickle Cell Disorder (SCD) patient

following an autopsy in Nigeria. This report describes the clinical profile and the autopsy findings in this index case.

### Case Report

In August 2001, Mr. A.R, a 22year old known sickle cell anaemia patient presented at the haematology day clinic with six month history of fever, weight loss, cough and right leg swelling. He was last seen at the clinic in February, 2000 with multiple peripheral lymphadenopathy and histology of the lymph node biopsy revealed Hodgkin's disease but he defaulted before any treatment could be instituted. Clinical examination showed a young man, cachectic, pale, jaundiced, acyanosed with generalized peripheral lymphadenopathy and bilateral pitting pedal oedema. There were limited chest movements and bilateral coarse crepitations. There were gallop heart rhythms with haemic murmur. There was tender hepatomegaly and subcutaneous nodules on the anterior abdominal wall. The chest x-ray showed bilateral coalescing diffuse fluffy opacities which are worse on the left. Bilateral hilar prominence and scalloping of the right mediastinal margin was also noted (Fig. 1). The electrolyte and urea were within normal limit but serum calcium was not done. The PCV was 17% and the retroviral test done was negative. A diagnosis of sickle cell anaemia with advanced lymphoproliferative disorder and congestive cardiac failure to rule out pulmonary tuberculosis was made. He was transfused with two units of packed cell and was placed on antibiotics, analgesics, and antifailure drugs, intravenous drugs with strict input and output monitoring.



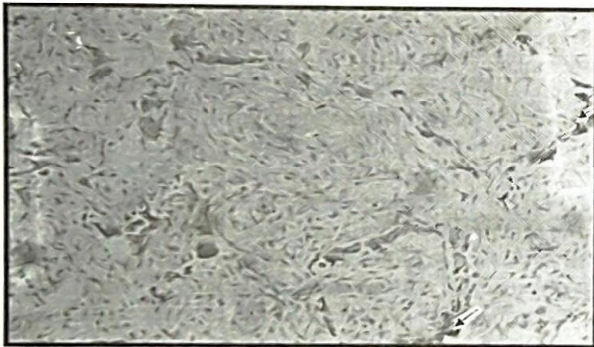
**Fig. 1:** Plain chest X-ray with legend. *Bilateral coalescing fluffy opacities (worse on the left). Also bilateral hilar prominence and scalloping of right mediastinal margin*

The clinical status of the patient did not improve and he died on the 5<sup>th</sup> day of admission following which an autopsy was done.



The autopsy findings were as follows:

- Lungs – The lungs were heavier than normal. There are multiple millet-sized whitish nodules on the pleural surface as well as within the parenchyma. Cut surfaces of these nodules showed chalky white materials with gritty sensation on cutting. There was also free flowing frothy fluid on the cut surface suggesting pulmonary oedema. The microscopy shows diffuse thickening of the alveolar wall and the presence of multiple variably – sized haematoxylin stained deposits (calcospherites) within the lung alveoli (Fig. 2).
- Heart - There was right ventricular hypertrophy but other chambers were normal
- Lymph node –The sections from the multiple lymph node enlargements were similar and revealed features diagnostic of Non-Hodgkins lymphoma (NHL). This was later confirmed by Immunohistochemistry.



**Fig. 2:** Microscopic section of the lung (Haematoxylin and Eosin stain x 160)

*Diffuse thickening of the alveoli wall with obliteration of the of alveoli spaces. Note multiple variably-sized haematoxylin-stained deposits (arrows).*

### Discussion

Pulmonary alveolar microlithiasis (PAM) is a condition that is characterized by progressive formation of calcific deposits within the alveoli in response to an unknown stimulus. PAM has no sex predilection and is seen in all ages, even in infants [13]. The disease seems to have familiar characteristics as noted in more than half of the cases reported worldwide [14,15].

The disease is usually insidious in onset and may extend over a period of 20 years [1]. Though most patients are asymptomatic, a few like in the case presented, have chronic cough which could be a direct consequence of the disease [16]. The chest x-ray finding of diffuse coalescing fluffy opacities were initially thought to be due to cardiogenic pulmonary edema with probable superimposed (pulmonary) infection. However, the autopsy finding of free

flowing frothy fluid on the cut surface of the lungs and intraalveolar microliths retrospectively revealed that the opacities seen on the radiography were produced by a combined presence of fluid and microliths within the alveolar air spaces. The chest X-ray findings of diffuse sand-like pulmonary opacities in this environment will arouse the diagnosis of pulmonary tuberculosis that was earlier made in this patient.

Pulmonary alveolar microlithiasis has been associated with progressive deterioration in the ventilation – perfusion balance that may result in dyspnoea, hypoxia and even cyanosis in some patients [17]. Eventually, some patient might end up with pulmonary hypertension and cor-pulmonale evidenced by right ventricular hypertrophy which was seen at autopsy in the case we presented [18]. At autopsy, the lungs are usually heavy and solid with gritty feeling while cutting through it as also seen in the case presented [18]. Though chemical analysis was not carried out in this case, it has been conclusively shown that microliths are composed principally of salts of calcium and phosphorus [8].

Diagnosis of PAM is based on high index of clinical suspicion, radiological investigations, bronchoscopy and bronchoalveolar lavage with a lavage fluid smear, and open lung biopsy [7,8,12,17]. Though PAM has no known specific treatment so far [9], the use of diphosphonate to inhibit microcrystal formation is being investigated [4]. Some workers have also proposed a combined heart/lung transplant to prolong the life of the patients [19]. It is important to note that this patient had a previous tissue diagnosis of Non-Hodgkins lymphoma; a thorough literature search did not reveal any causal relationship between PAM and NHL.

The import of this report is to arouse the clinician awareness of pulmonary alveolar microlithiasis and to include it to differential diagnosis when investigating patients with diffuse opacities of the lungs.

### References:

1. Radosavljevic G, Rebic P and Mandaric I. Microlithiasis alveolaire pulmonaire chez 2 freres. (Pulmonary alveolar microlithiasis in 2 brothers). *Revue de pneumologie clinique*, 1988; 11 (4): 202-204.
2. Harbitz F: Extensive calcification of the lungs as a distinctive disease. *Arch Intern Med*. 1918; 21: 139-146.
3. Pühr L: Mikrolithiasis alveolaris pulmonum. *Virchows Arch Pathol Anat* 1933; 290: 156-160.
4. Al-kubaisi W, Al-Alwan N and Al-Nu'aimi K. Pulmonary alveolar microlithiasis: an overlooked disease in Iraq. *Eastern Mediterranean Health Journal*, 2000; 6 (5): 1130-1135.
5. Ozcelik U, Gulsum M, Gocimen A *et al*. Treatment and follow up of pulmonary alveolar microlithiasis with disodium edetate: radiological demonstration. *Pediatr Radiol* 2002; 32 (5): 380-383.



6. Mariotta S, Guidi L, Papale M, Ricci A and Bisetti A: Pulmonary alveolar microlithiasis: review of Italian cases. *Eur J. Epidemiol* 1997; 13: 587-590, (ISI) (Medicine).
7. Wallis C, Whitehead B, Malone M and Dinwiddie R. Pulmonary alveolar microlithiasis in childhood; diagnosis by transbronchial biopsy *Pediatr Pulmonol* 1996; 21 (1): 62-64.
8. Moran CA, Hochholzer L, Hasleton PS, Johnson FB and Koss MN: Pulmonary alveolar microlithiasis. A clinicopathologic and chemical analysis of seven cases. *Arch Pathol Lab Med* 1997; 121: 607-611, (ISI) (Medline)
9. Prakash UB, Barham SS, Rosenow EC, Brown ML and Payne WS: Pulmonary alveolar microlithiasis. A review including ultrastructural and pulmonary function studies. *Mayo Clin Proc* 1983; 58: 290-300. (ISI) (Medline)
10. Schmidt H, Lordor U, Kitz R, Zielen S, Abrens P and Konic R: Pulmonary alveolar microlithiasis in children. *Pediatr Radiol* 1996; 26: 33-36, (ISI) (Medline)
11. Sosman MC, Dodd GD, Jones WD and Pillmore GU: The familiar occurrence of pulmonary alveolar microlithiasis. *Am J. Roentgenol Radium Ther Nucl Med* 1957; 77: 947-1012, (ISI).
12. Onadeko BO, Abioye AA, Beetlestone CA, Adetuyibi A, Cooke AR and Sofowora EO: Pulmonary alveolar microlithiasis. *Postgraduate medical journal*, 1977; 53, 165-167.
13. Ariole P, Bouquillard E, Barneon G, Amsallem F, Voisin M and Jean R: Microlithiase alveolaire de l'enfant. Apport du lavage broncho-alveolaire. (Alveolar microlithiasis in children. Contribution of bronchiolar lavage.) *Archives francaises de pediatrie* 1987; 44 (4): 291-293.
14. Shah MS, Nanavati KI, Airon N, Shah RR and Joshi BD. Case report- Pulmonary alveolar microlithiasis. *Ind J Radiol Imag* 2003; 13 (3): 277-279
15. Senyigit A, Yaramis A, Gurkan F *et al.* Pulmonary alveolar microlithiasis: A rare familiar inheritance with report of six cases in a family. Contribution of six new cases to the number of case reports in Turkey *Respiration* 2001; 68: 204-209
16. Turktas I, saribas S and Balkanc F. Pulmonar alveolar microlithiasis presenting with chronic cough. *Postgraduate Medical Journal* 1993; 69 (807): 70-77.
17. Ishida T, Matsumura Y and Miyake A. (A Case of Pulmonary alveolar microlithiasis showing respiratory failure after 33 years and revealing microliths in bronchioalveolar lavage). *Nihon Kyobu shikkan gakkai Zasshi*, 1991; 29 (5): 627-731.
18. Millard M. Lungs, pleura, and mediastinum. In Anderson W A D (ed). *Pathology* 6<sup>th</sup> Ed, Mosby 1971; 921-922.
19. Tribel HJ, Von Hulst M and Schofer M. Fortgeschrittene microlithias alveolaris pulmonum. (Advanced pulmonary alveolar microlithiasis.) *Rntgen-blatter*, 1987; 10(9):286-288

Received: 23/07/04

Accepted: 25/02/05