

**AFRICAN JOURNAL OF
MEDICINE
and medical sciences**

VOLUME 31, NUMBER 1 MARCH 2002



**EDITOR:
B. O. OSOTIMEHIN**

**ASSISTANT EDITOR:
A. O. UWAIFO**

ISSN 1116 — 4077

Pattern of active pulmonary tuberculosis in human immunodeficiency virus seropositive adult patients in University College Hospital, Ibadan, Nigeria

OB Awoyemi, OM Ige and BO Onadeko

Department of Medicine, University College Hospital, Ibadan, Nigeria.

Summary

Fifty-eight confirmed HIV-seropositive adult patients were studied. All subjects were interviewed and examined. Subjects with positive respiratory symptoms and signs had their sputum examined and cultured for *Mycobacterium tuberculosis* (M. tuberculosis). Their chest radiograph, full blood count (FBC) and erythrocyte sedimentation rate (ESR) were also estimated. Subjects with Pulmonary tuberculosis were treated using directly observed therapy short course (DOTS) regimen. Sixty-three percent of subjects were positive for *Mycobacterium tuberculosis* on direct smear and/or culture. Sputum acid fast bacilli (AFB) positive subjects who completed the intensive phase of antituberculous drugs were sputum converted at 2 months. The chest x-ray finding at diagnosis showed 2 subjects (11%) with normal chest x-ray; localised lesion in 7 (37%) subjects; diffuse lesion in 7 (37%); pulmonary cavities in 3 (16%); miliary pattern in 2 (11%); pleural effusion in 2 (11%); hilar adenopathy in 2 (11%). Repeat chest-x-ray at 3 months showed complete clearance of pulmonary infiltrates in 29% whilst 71% had appreciable improvement in radiologic features. The study showed that although chest x-ray may be "normal" in sputum AFB positive HIV infected individuals, radiologic picture tends to be more diffuse and extensive. This study was therefore undertaken to determine the pattern of PTB in HIV seropositive adult patients in U.C.H., Ibadan.

Keywords: *Human immunodeficiency virus, active pulmonary tuberculosis.*

Résumé

Une étude était faite du cinquante huit adultes malades séropositifs. Tous les sujets ont passé l'entrevu et sont examinés. Les sujets avec des signes et symptômes respiratoire positif ont subi un examen de leurs expectorations qui étaient cultivé pour le tuberculoses micobactarium (tuberculoses M). La radiographie de leur poitrine, une numération globulaire complète (NGC) et le taux de la sédimentation d'erythrocyte (TSE) étaient aussi estimé. Les sujets souffrant de TBP sont soigné en employant le régime court de la thérapie directe observé. Soixante-trois pour-cent des sujets ont testé positif de tuberculoses M sur la frottis directe et/ou culture. Les sujets positifs de bacille d'acide vite d'expectoration (AFB) qui ont complété la phase intensive des médicaments ante tuberculose ont été converti en expectoration à 2 mois. Lors de diagnoses des résultat de radio poitrinaire, on a trouvé une radio poitrinaire en 2 sujets (11%), la lésion localisé en 7 sujet (37%) la lésion localisée en 7 sujets (37%), la lésion diffuser en 7 (37%), les cavités pulmonaires en 3 (16%), le désigne miliaire en 2 (11%), l'effusion de plèvre en 2 (11%), l'adénopathie d'hilare en 2 (11%). Une deuxième radio poitrinaire faite au troisième mois, a montré un déblaiement des infiltrats pulmonaires 29% tandis que 71% avait une amélioration appréciable caractéristique radiologique. L'étude a montré que bien que la radio de poitrine puisse être

normale, chez les individus infectés de l'expectoration AFB et séropositifs, les images radiologique tends à être plus diffusé et extensif. L'étude était alors entreprise pour déterminer la manière de TBP chez les malades séropositif au centre hospitalier universitaire d'Ibadan.

Introduction

Tuberculosis (CTB) has been known to afflict man since the ancient time [1,2] and it still remains an important disease of man [3]. TB is highly prevalent in the tropics [4-6].

TB affects almost every organ in the body, but PTB accounts for more than 80% of TB cases [7]. TB is most commonly transmitted via the respiratory route [8,9]. Immunosuppressive states like diabetes mellitus (DM), chronic renal failure (CRF), malnutrition, malignancies and HIV infection are known to predispose to development of the disease. Infection with HIV leads to a progressive destruction of cellular immunity and hence HIV infection would usually not be susceptible. Approximately 80% of AIDS patients die as a direct result of an infection other than HIV, with infections due to opportunistic infections heading the list [10]. Throughout the developing world, the high risk of infections with *Mycobacterium tuberculosis* has led to the majority of adults being infected [11,12]. In most developing countries, TB is clearly the most important opportunistic infection observed among HIV infected patients. Cohort studies [13-15] have shown that the risk of developing active TB among HIV infected persons also infected with *M. tuberculosis* is much higher than among *M.*

Tuberculosis infected HIV seronegative persons. While the life time risk of developing TB in persons with *Mycobacterium tuberculosis* infection alone is estimated to be only 5-20% [16] the annual risk of developing active TB in persons co-infected with HIV and *Mycobacterium tuberculosis* ranges from 5 to 15% with estimated life time risk above 30% [8-13]. The other atypical mycobacteria are rare in Africa [17].

As a way of reducing the transmission of TB in the community, it is important to recognise and treat PTB whenever it is present. Untreated TB is said to accelerate the course of HIV disease [18-19] so to reduce the morbidity and mortality of - HIV infected individuals. It is important to recognise and treat TB in them.

Recognising PTB in HIV - infected patients requires a renewed knowledge of the various patterns of presentation of PTB in these patients. Before the advent of HIV, clinical pattern of PTB in affected individuals has been well documented and has been passed down to generations of health workers. For example hilar node enlargement is seen usually in primary PTB, with affectation of mid and lower lung zones and sputum in primary PTB is devoid of *Mycobacterium tuberculosis*. Primary PTB is however uncommon in the African adult [20] before the advent of HIV infection. Post-primary PTB on the other hand is characterised by pulmonary features of consolidation or fibrosis or cavitations; and with a predilection for apical posterior segment of the upper lobe or superior segment of the lower lobe [20], and usually expectoration of *M. tuberculosis* in sputum. The advent

of HIV infection however has profoundly influenced the epidemiology and clinical expression of TB[21]. It has brought with it a 'new' PTB with diverse features[9,16,22,25]. For example HIV immuno-suppressed patients with PTB have fewer number of AFB on sputum examination²⁴. The chest x-ray is often atypical[23]. Pitchenik and Rubison[23] noted hilar and/or mediastinal adenopathy in the initial pre-treatment chest radiographs in 50% of studied patients. Twenty-nine percent had localised pulmonary infiltrates, out of which 18% were localised to the upper lobes. There were no pulmonary infiltrates in 35% and no abnormalities detected in 12%. Only 6% had a chest radiograph typical of adult onset reactivation TB, i.e., localised pulmonary infiltrates involving the upper lung fields without hilar or mediastinal adenopathy. Some AIDS patients with sputum positive PTB have normal chest radiographs[9,23].

In absence of effective treatment for active TB, a chronic wasting course is usual and death ultimately supervenes. The overall death rate of untreated active TB approaches 60% and the median course to death is about 2 $\frac{1}{2}$ years[9]. In HIV infected patients, death has been attributed to TB in 40% of autopsied cases and untreated TB has been shown to accelerate the course of HIV infection[18,19]. Currently available first line antituberculous drugs when used in short course chemotherapeutic regimen, achieve rapid sterilization of sputum within 2-3 months[24-25] and result in radiographic clearance or improvement within 2-4 months[23]. In HIV/TB co-infection, Small et al[26] found out that in patients who comply with treatment, conventional therapy with short course chemotherapy s(SCC) results in rapid sterilisation of sputum, radiographic improvement and low rate of relapse.

Methodology

The study was carried out in General Out patient, Medical Outpatient, Surgical outpatient departments and wards of UCH, Ibadan, for one year between October 1998 and September 1999. A total of 73 consecutive adult patients aged 15 years and above confirmed by western blot serology (in UCH) to be infected with HIV were seen, but only 58 patients who satisfied the necessary criteria were studied.

The inclusion criterion was adult patients infected with HIV. While the exclusion criteria are patients with diabetes mellitus, (D.M.), chronic renal failure (CRF), alcoholics, patients with known malignancies and refusal to give informed consent.

History and physical examination were carried out on each subject. The information obtained were entered into a prepared questionnaire. The prepared questionnaire included patients personal data. The thrust of the interview was directed at elucidating clinical symptoms suggestive of PTB such as cough with sputum production, haemoptysis, difficulty in breathing, chest pain, weight loss, fever, night sweat; occurring either singly or in combination. Interview also included history of recent exposure to an index case of PTB, previous history of tuberculosis in the subjects and history of treatment for tuberculosis. Other parts of the interview were designed to exclude DM and CRF.

Physical examination of subjects included general examination to detect pallor, weight loss, lymphadenopathy, and for digital clubbing. A detailed examination of the chest was carried out on each subject particularly to detect features of PTB such as apical flattening, tracheal deviation, reduced chest movement, reduced chest expansion, percussion note, diminished breath sound, and for bronchial breath sound, in any of the lung fields.

Investigation included

Sputum microscopy: For patients with productive cough, 3 sputum specimens collected into sterile containers were examined for AFB using the Ziehl-Neelsen (ZN) staining method. Sputum culture was done on Lowenstein-Jensen medium.

Chest radiograph: Standard postero-anterior chest radiograph done in the UCH Radiology department was obtained in subjects with symptoms and signs suggestive of a pathology in the chest. The chest x-ray were specifically reviewed for evidence of pulmonary tuberculous lesions such as pulmonary infiltrate, cavities, nodular and streaking opacities, fibrosis, hilar adenopathy and pleural effusions. All the films were reviewed with a consultant radiologist.

Haematologic evaluation: Ten millilitres of venous blood was obtained from each subject for full blood count (FBC), erythrocyte sedimentation rate (ESR), serum electrolytes, urea and creatinine and the values were entered into the questionnaire. Diagnosis of PTB was made when a subject has

- (i) at least 2 samples of sputum positive for AFB by ZN staining method, and/or
- (ii) sputum culture that is positive for M.tuberculosis, and/or
- (iii) Chest radiograph pattern that is highly suggestive of PTB that does not improve with antibiotics but shows improvement with chemotherapeutic trial of antituberculosis drugs.

Treatment and follow up

Patients found to have PTB were enrolled in the Tuberculosis unit under the TB treatment programme being sponsored by Damien Foundation in UCH. The treatment regimen being used under the programme is as recommended by the National Tuberculosis and Leprosy Control Programme Guidelines; it consists of Daily Observed Therapy Short Course (DOTS) using rifampicin, pyrazinamide, ethambutol, isoniazid and thiacetazone. Specifically, it consists of an initial intensive phase of 2 months using: Rifampicin 10mg/kg (maximum 600mg), Pyrazinamide 30mg/kg (maximum 2g), Ethambutol 25mg/kg (maximum 1.2g), Isoniazid 5mg/kg (maximum 300mg) daily and the continuation phase of 6 months using: Isoniazid 5mg/kg (maximum 300mg), and Ethambutol 15mg/kg body weight daily.

Subjects with tuberculosis who were considered very ill were admitted into the ward.

Follow-up

Subjects with PTB present daily to MOP to obtain their antituberculosis drugs in the presence of the nursing staff at MOP (DOTS); while subjects on admission in the wards were on a daily basis, being served and observed to take their antituberculosis drugs by the nursing staff in the ward of admission. In addition, subjects were reviewed weekly to monitor clinical response to treatment and a standing instruction was given that the researcher should be contacted in case medical attention is required.

Clinical response to treatment were assessed subjectively and objectively. Subjective assessment of symptoms included feeling of well - being, subsidence of cough and fever. Objective assessment included weight gain and defervescence. Assessment was categorised as: (a) improved (b) unchanged, (c) worsened or (d) died.

Sputum samples were examined for presence of AFB at 2 months of commencement of anti-tuberculosis drugs. Repeat chest radiographs were carried out at 3 months of antituberculosis drugs. The radiographic findings were compared with the initial pre-treatment chest radiograph and were classified as (a) resolved, (b) improved, (c) worsened or (d) unchanged

In this study, the level of circulating CD4+ T-lymphocytes was not estimated because the facility for this was not available.

Statistical method

All available questionnaires were entered and analysed using the statistical packages EPI-INFO version 6.0 produced by WHO in collaboration with Centre for Disease Control and Prevention.

Initial data exploration was done by examining the frequency distribution of all the variables present in the questionnaire. Tables and charts were constructed for the presentation of the result. Proportions and percentages were used to describe the demographic characteristics of subjects, comparison of selected symptoms and some clinical variables; while mean values and standard deviations were used for clinical findings and variables that are quantitative data.

Also chi-square test of association was used to compare presence of selected symptoms and some clinical variables between subjects with HIV and HIV/PTB co-infection. While the means value of continuous clinical variables were compared between the HIV and HIV/PTB co-infected subjects using student-test. All statistical tests were two-tailed carried out at 5% probability level.

Ethical committee approval

The study was approved by the Joint Ethical Committee of the University College Hospital/University of Ibadan.

Result

Symptoms

Table 1 shows the break down of symptoms suggestive of PTB in subjects with HIV infection studied. All 19 (100%) subjects with HIV/PTB co-infection had chronic cough.

Three out of nineteen (15.8) subjects with HIV/PTB co-infection presented with haemoptysis. One HIV seropositive subject without PTB also presented with haemoptysis.

Table 1: Comparison of presence of selected symptoms among HIV seropositive adult subjects with and without PTB

Symptoms	HIV + PTB		HIV		X ²	P-value
	n=19	(%)	n=39	(%)		
Chronic cough	19	(100)	21	(53.8)	12.7154	0.0004
Haemoptysis	3	(15.8)	1	(2.6)	3.4802	0.0621
Fever	16	(84.2)	30	(76.9)	0.4135	0.5202
Night Sweat	12	(63.2)	16	(41)	2.5062	0.1134
Chest Pain	13	(68.4)	16	(41)	2.5062	0.000001
Difficult in breathing	12	(63.2)	4	(10.3)	17.8983	0.000001
Contact with index case of PTB in recent yrs	2	(10.5)	0	(0)	4.2519	0.0392
Previous History of PTB	2	(10.5)	0	(0)	4.2519	0.0392
Previous treatment for PTB	2	(10.5)	0	(0)	4.2519	0.0392
Immunization with BCG	9	(47.4)	19	(48.7)	0.0093	0.9231

Table 2: Comparison selected clinical findings in HIV seropositive adult patients with and without PTB

Signs	HIV + PTB n=19	HIV n=39 (%)	P-value
BMI (kg/m ²) range	11.72-21.67	11.61-35.14	0.1973 NS
means (SD)	16.98 (2.79)	18.41 (4.35)	
Temperature(°C)			
range	37-38	36.4-39.8	0.4488
mean SD	37.4 (0.30)	37.3 (0.53)	
Significant peripheral lymphadenopathy	7 (36.9%)	17(43.6%)	0.6243
Signs of pulmonary consolidation	15 (78.9%)	1 (5.1%)	0.00001
Signs of Pulmonary Fibrotic lesions	1 (5.2%)	0 (0%)	0.1484
Signs of pleural effusion	1 (2%)	0 (0%)	0.1484
'Normal' chest examination	2 (10.5%)	35 (89.7%)	0.00001

Fever occurred in 16 out of 19 (84.2%) subjects with HIV/PTB co-infection, while 30 out of 39 (76.9%) subjects with HIV infection alone had fever. The difference is not statistically significant ($P > 0.05$).

Thirteen out of nineteen (68.4%) subjects with HIV/PTB co-infection had chest pain. This differs significantly ($P = 0.00001$) from subjects without PTB in whom only 5 out of 39 (12.8%) subjects gave a positive history of chest pain. Difficulty in breathing was significantly associated with HIV/PTB co-infection, occurring in 12 out of 19 (63.2%) subjects compared with 4 out of 39 (10.3%) subjects with HIV infection alone. History of recent contact with index case of PTB; previous history of PTB; and previous treatment for PTB were obtainable only in subjects with HIV/PTB co-infection. The differences are statistically significant ($p = 0.0392$).

Table 3: Summary of clinical characteristics of HIV seropositive adult subjects with active PTB at diagnosis

Characteristic	Value
Age (years): range	19 - 53
means (SD)	32.89 (9.45)
Sex: Male: Female ratio	7 : 12
	12 : 2
BMI (kg/m ²) range	11.72 - 21.67
Means	11.98 - 2.79
Sputum AFB Positive	¹¹ / ₁₉ (58%)
Sputum AFB Negative	⁸ / ₁₉ (42%)
Culture Positive for <i>M. tuberculosis</i>	¹¹ / ₁₉ (58%)
Culture Negative for <i>M. tuberculosis</i>	⁸ / ₁₉ (42%)

Physical examination

Table 2 highlights the findings on selected clinical examination of subjects with HIV/PTB co-infection compared with subjects with HIV infection alone.

There was no statistically significant difference in the occurrence of significant peripheral lymphadenopathy in subjects with and without PTB.

The clinical examination of the chest revealed significant findings of signs of pulmonary consolidation (reduced chest movement, increased tactile fremitus, dull percussion note,

bronchial breath sound, plus or minus crepitations) in 15 out of 19 (78.9%) subjects with HIV/PTB co-infection compared with subjects with HIV infection alone in whom only 1 out of 39 (5%) subjects had signs of consolidation (P = 0.00001). Other abnormalities detected in subjects with HIV/PTB co-infection included pulmonary fibrotic lesions (Significant tracheal deviation or mediastinal shift reduced chest movement, dull percussion note) in 10.5%, pulmonary cavitory lesions (amphoric breath sound) in 5.2% and signs of pleural fluid collection (stony dull percussion note) in 5.2%.

No abnormality was detected on clinical chest examination of 2 out of 19 (10.5%) subjects with HIV/PTB co-infection while chest examination was normal in 35 out of 39(89.7%) subjects with HIV infection alone. This difference between the two groups is statistically significant. Clinical characteristic of HIV seropositive subject with active PTB Table 3 summarises the clinical characteristics of HIV seropositive adult subjects with PTB.

Table 4: chest x-ray findings in HIV seropositive adult subjects with PTB (AT diagnosis)

Finding*	N	Percent
No abnormality	2	11
Localised infiltrate /fibrotic lesion/consolidation	7	37
Diffuse interstitial/ streaky/reticulonodular lesions	7	37
Pulmonary cavities	3	16
Pleural effusion	2	11
Miliary TB	2	11
Hilar adenopathy	2	11

*Some have multiple abnormalities

The ages of subjects ranged from 19 years to 53 years, with a mean age of 32.89 years. There were more females HIV seropositive subjects with PTB, with a male:female ration of 1.2:2. The BMI of subjects ranged from 1.72 to 21.67 with a mean of 16.98 11 out of 19 subjects (58%) were sputum AFB positive on microscopy and 8 subjects (42%) were sputum negative on microscopy. Sputum culture for *M. tuberculosis* was positive in 11 out of the 19 subjects. In one subject where sputum

Table 5: Zone of radiologic abnormalities in HIV seropositive adult patients studied

Radiologic Zone	n - 17	
	Unilateral n = 7 Number (%)	Bilateral n = 10s Number (%)
Upper zone only	1 (6)	1 (6)
Mid zone only	1 (6)	-
Lower zone only	1 (6)	1 (6)
Upper + Middle zones	-	1 (6)
Mid + Lower zone	1 (6)	-
Upper + Middle Lower zones	3 (17)	7 (41)

microscopy was negative for AFB. culture was positive while one other subject who had been previously treated for PTB and self medicating before presentation. sputum AFB was positive but culture was negative. TABLE 3

Chest x-ray

Table 4 shows the findings on chest x-ray of subjects with HIV/PTB co-infection.

Pulmonary cavities (figure 1) were seen in 3 (16%) subjects while pleural effusion and miliary pattern PTB were seen in 2(11%) subjects respectively. Hilar adenopathy (figure 2) was also noted in 2 (11%) subjects.

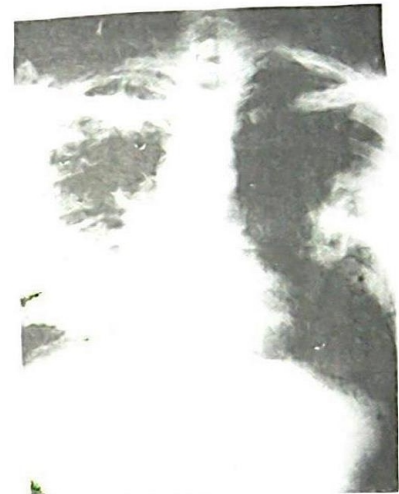

Fig.1: Chest X-ray of a 35 year old male subject with cavitory lesion. There are the reticulonodular opacities Chest X-ray of a 35 year old male subject with cavitory lesion There are the reticulonodular opacities in the right lung field and left upper and midzones Multiple cavities are seen in the right lower zone

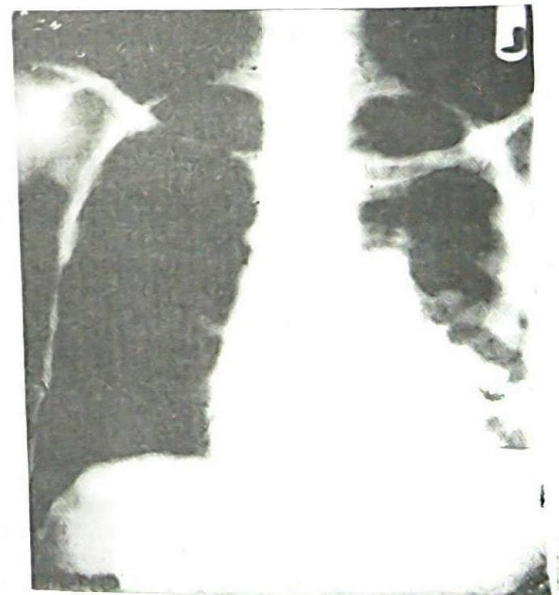


Fig. 2: Chest X-ray of a 47 year old female subject with left hilar adenopathy Multiple plate like atelectatic shadows in the lower half of the left lung Reticulo-nodular opacities in the left upper zone Associated elevation of the left hemidiaphragm Prominence of the left hilar shadow

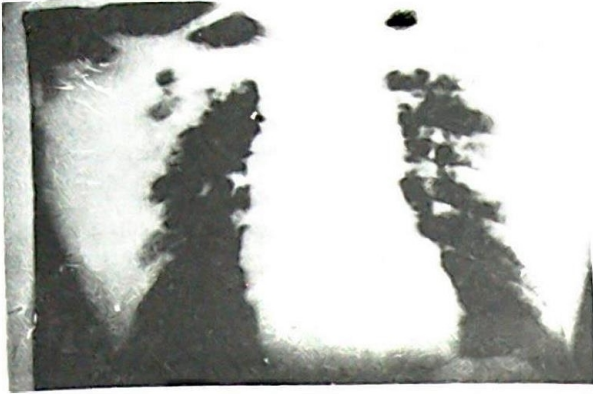

Fig.3: Chest x-ray of 45 year old male subject with affection of all the lung zones.

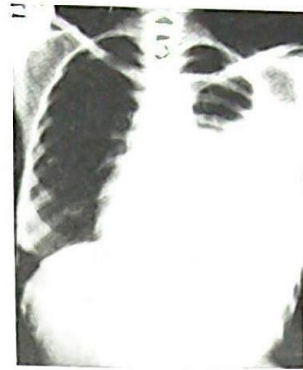


Fig. 5: Chest x-ray of a 26 year old female subject. With HIV/PTB and pleural effusion. A homogenous opacity in the left mid and lower with meniscus sign. The lower two thirds of the cardiac margin and the ipsilateral hemidiaphragm are obscured by the aforementioned opacity. Wasting of soft tissue of the lateral chest wall.

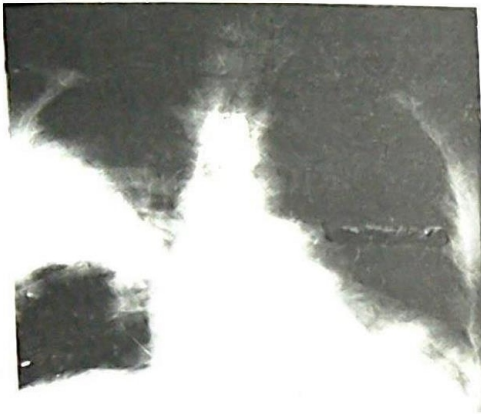

Fig.4a: Chest x-ray of 32 year old male subject with HIV/PTB co-infection. Initial chest x-ray showed a homogenous opacity of the axillary segment of the right lower lobe. There is also hazy opacity of the left lower zone obliterating the hemidiaphragm. The presence of silhouette sign makes this a consolidation rather than pleural fluid collection.

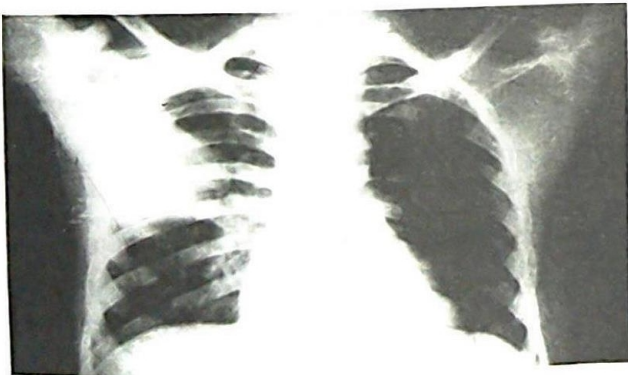


Fig. 4b: Same subject in fig 9a after a 2 week course of antibiotics, the left lower lobe opacity has cleared. The consolidation at the apical segment of right lower lobe has not completely resolved, though minimal improvement; raises possibility of PTB as distinct from lobe consolidation, which is probably non-mycobacteria.

Clinical response to therapy

14 out of the 19 subject with HIV/PTB co-infection were able to commence antituberculous drugs. 4 subjects died before antituberculous drug could be commenced (2 of these had normal chest x-ray). One subject did not return to start treatment after diagnosis of active PTB was confirmed.

Two out of the 14 (14%) subjects started on anti-tuberculous drugs improved clinically (reduction in frequency of cough, reduction in sputum production, disappearance of fever, reduction in chest pain and weight gain) in the second week of starting antituberculous drugs: 9(64%) improved in the third week of treatment. 2 subjects did not improve until the fourth week. 2 subjects defaulted from follow-up before the end of the study. One of them after initial clinical improvement, another defaulted at the fourth week before measurable improvement.

All the 6 sputum positive cases who completed the intensive phase of anti-tuberculous drugs were sputum converted at the end of 2 months.

Figure 4a and 4b show the chest X-ray changes with treatment while Figure 5 shows left sided pleural effusion which also resolved. Repeat chest x-ray (at 3 months) of the 12 subjects who completed the study showed that there was complete clearance of the radiologic abnormalities in 4 subjects, while in the remaining 8 subjects, there was appreciable improvement in the radiologic features. Worsening of the chest radiograph was not observed in any subject.

Discussion

In this study, chronic cough is the major respiratory symptom in HIV seropositive adult subjects with active PTB just as it is the case in individuals who are seronegative[4]. Other symptoms of active PTB like chest pain (68.4%) difficulty with breathing (63.2%) occur more commonly in subjects with HIV/PTB co-infection when compared with subjects with HIV infection without active PTB. These findings agree with early workers[12-14].

As found out in this study 89% of subjects with HIV/PTB co-infection had no history of recent contact with index case of PTB. This is consistent with what was found by Selwyn et al[13], in which 88% seropositive subjects in whom active tuberculosis was diagnosed during their study period were known to have had latent (determined by tuberculin test) tuberculosis infection at the time of entry in their study. Ten percent of the subjects with HIV/PTB co-infection in this study also had been previ-

ously treated for PTB at a time not more than 5 years. This also is consistent with the known effect of HIV infection causing increased risk of recurrent disease following certain therapeutic regimen[21].

The finding of wasting, fever, and peripheral lymphadenopathy is not significantly different between HIV seropositive subjects with or without active PTB. This is similar to what was found by Elliot et al[22]. However, in this study the typical finding of reactivation TB such as signs of pulmonary consolidation and fibrotic lesions are more common and detectable on physical examination of subjects with HIV/PTB.

In this study, sputum microscopy for AFB on direct smear is positive in 58% of subjects, this is close to 62% sputum AFB positivity in HIV seropositive subjects found by Small et al[26] and 60% found by Elliot et al[22]. These subjects being sputum positive for AFB make them a potential source of infection within the community, in addition to accelerating the progression of their own disease.

The chest X-ray findings in these patients are diverse. Selwyn et al[13] in their study also showed that the radiologic pattern in HIV patients with PTB are diverse. In 11% of the subjects the chest X-ray was normal. This is similar to what was found by Pitchenic et al[23] where 1.7% culture positive PTB cases had normal chest X-ray. However unlike subjects in this study where the pulmonary cavities were seen in 3 subjects, (16%) Pitchenic et al[28] did not observe any pulmonary cavity in their series; but Elliot et al [22] found pulmonary cavities in 48% of subjects with HIV/PTB co-infection. Similar to what has been found in other studies[22,23] the classic upper zone abnormality is not common in HIV patients with active PTB, rather chest X-ray abnormalities appeared more commonly diffuse affecting the 3 radiological zones either unilaterally (17%) or bilaterally (41%). Mid and lower radiology zone affection were also common. Henshaw[20] had shown in a previous study in HIV seronegative adult Nigerian subjects that reactivation PTB mostly (88% of cases) affects the upper lobe, more on the right (48%) than on the left (40%).

This study agrees with the findings of Small et al[26] that all the subjects who were placed on anti-tuberculosis chemotherapy showed good initial clinical response to therapy. In 78.5% of the cases, there was feeling of well being, weight gain and reduction in the frequency of cough at the end of the 3rd week on the anti-tuberculosis drugs.

Also at the end of the intensive phase, the 6 sputum AFB positive subjects who completed the intensive phase were all sputum converted. A similar sputum conversion rate was found by earlier workers[26,27].

Conclusion and recommendation.

The clinical picture of active PTB in HIV seropositive individual is varied; however, the radiologic picture tends to be more diffuse and extensive. A sizeable proportion of HIV seropositive adult subjects with active PTB shed *M. tuberculosis* in their sputum, hence they are a potential source of transmission of TB in the community. HIV disease is a chronic illness and PTB can occur at an early stage in HIV infected patients and if because of the stigma associated with HIV infection these patients are abandoned, those of them with active PTB will continue to disseminate the tubercle bacilli. This may adversely affect aims of National Tuberculosis and Leprosy Control Programme in that whatever public health gain is expected to accrue from treatment of HIV seronegatives with smear positive PTB will be lost in the untreated HIV infected or AIDS individuals with PTB.

As shown in this study, HIV regimen infected subjects with PTB who comply with treatment respond to short course chemotherapy.

Individuals with HIV/PTB co-infection should be actively identified and encouraged to use their antituberculosis drugs even if there are financial constraints in obtaining antiretroviral drugs. This will limit the spread of TB in the community and also reduce early mortality in AIDS patients.

References

1. Roelsgarrd E, Reider HL, Cauther FM; *et al.* Tuberculosis in tropical Africa: An epidemiological study. Bull. Wild Health Org. 1964; 30: 459-518.
2. Kleeburg MM. Tuberculosis and other mycobacterioses disease transmitted from Animal to Man; 6th Edition, 1975, 303 - 304.
3. Sudre P, Ten Dam G, and Kochi A. Tuberculosis, global overview of the situation today. Bulletin of the world health organization 1992; 70: 149-159.
4. Lauckner JR. The treatment of tuberculosis in the tropics. J. Trop. Med. Hyg. 1959; 62:1-9
5. Onadeko BO. Tuberculous pleural effusion; clinical pattern and management in Nigerians. Tubercle 1978; 59: 269-275
6. Edington GM, and Gilles HM. In: pathology in the tropics. London: The English book society and Edward Arnold (Publishers) Limited, 1976; 391 - 399
7. Orjioko CJ, Harries AD, Mahar D; *et al.* In: National Tuberculosis and Leprosy Control Programme. Worker's Manual Second edition 1 - 43.
8. Mario C, Raviglione M, and Paul PN. Epidemiology of tuberculosis. In: AIDS and Respiratory Medicine. First Edition 1997. Chapman and Hall (Publishers) 117 - 141.
9. Daniel TM. Tuberculosis. In: Harrison's principles of Internal Medicine. Thirteenth Edition. Mc GRAW-HILL, Inc. 1994; 710 - 718.
10. Lane HC. Recent advances on the management of AIDS - related opportunistic infections. Ann. Inter. Med., 1994; 120: 945-55.
11. Gilks CF, Brindle RJ, Otieno LS; *et al.* Extra pulmonary and disseminated tuberculosis in HIV-1 Seropositive patients presenting to the acute Medical Services. In Nairobi. AIDS. 1990; 4: 981-985.
12. Lucas SB, Hounnou A, Peakcock C; *et al.* The mortality and pathology of HIV infection in a West African City. AIDS 1993; 7: 1569-1579.
13. Selwyn PA, Pape JW, Liautand B; *et al.* High risk of active tuberculosis in HIV-infective drug users with cutaneous anergy. Journal of the American Medical Association. 1992; 268: 504-509.
14. Allen S, Batungwanayo J, Kerlikowske K; *et al.* Two year incidence of tuberculosis in cohorts of HIV-infected and uninfected urban Rwandan women. Am Rev. Resp. Dis. 1992; 146: 1439- 1444.
15. Antonucci G, Girardi E, Raviglione HC. *et al* Risk factors for tuberculosis in HIV-infected persons. A

- prospective cohort study. *J. Am. Med. Ass.* 1995; 274: 143 –148
16. Sutherland I. Recent studies in the epidemiology of tuberculosis Based on the risk of being infected with tuberculosis basilli. *Advances in Tuberculosis Research.* 1976; 19: 1-63.
 17. Fauci AS, and Lane HC. Human Immunodeficiency virus (HIV) Disease: AIDS and Related Disorders. In *Harrison's Principle of Internal Medicine.* Thirteenth Edition. Mc GRAW-HILL, Inc. 1994; 1566 - 1618.
 18. Scott GM, and Darbyshire JH. Management of Mycobacterial infections in AIDS. In: *AIDS and Respiratory Medicine* first edition 1997. Chapman and Hall (Publishers) 178 - 197.
 19. Mc Carthy M. Active tuberculosis boiost HIV replication. *Lancet* 1996; 348: 9024-9035.
 20. Henshaw JE. Observation on the chronicity of pulmonary tuberculosis in African. *W. Afr. Med. J.* 1959; 8: 229 - 236.
 21. Adam S, Malin B, and Kevin M. De Cock. Clinical Aspects of Adult tuberculosis in HIV-infected patients. In: *AIDS and Respiratory Medicine.* First edition 1997; Chapman and Hall (Publishers) 143 - 152.
 22. Elliot A, Luo N, Tenbo G; *et al.* The impact human immunodeficiency virus on tuberculosis in Zambia: a cross-sectional study. *Brit. Med. J.* 1990; 301: 412-415.
 23. Pitchenik AE, Rubinson H.A. The radiographic appearance of tuberculosis in patients with acquired immune deficiency syndrome AIDS and pre-AIDS. *Am. Rev. Respir. Dis.* 1985; 131: 393 - 396.
 24. Brindle RJ, Nunn PP, Githui W; *et al.* Quantitative bacillary response to treatment in HIV-associated pulmonary tuberculosis. *Am. Rev. Respir. Dis.* 1993; 147: 958-961.
 25. Onadoko BO, Sofowora EO. Daily short course (6 months chemotherapy for treatment of pulmonary tuberculosis in Nigerians. A preliminary report. *Afr. J. Med. Sci.* 1978; 7: 175 - 181.
 26. Small PM, Schecter GF, Goodman PC; *et al.* Treatment of tuberculosis in patients with advanced human immunodeficiency virus infection. *N. Engl. J. Med.* 1991; 324: 289 - 294.
 27. Ige OM, Bakare NA, and Onadoko BO. Mordified short course chemotherapy of pulmonary tuberculosis in Ibadan, Nigeria – a preliminary report. *Afr. J. Med Sci.* 2000;29:51-53.